

Small Intestinal Manometry

M. B. HANSEN

Department of Surgical Gastroenterology D, Glostrup University Hospital of Copenhagen, Copenhagen, Denmark

Received December 1, 2001

Accepted March 20, 2002

Summary

Gastrointestinal motility is an integrated process including myoelectrical and contractile activity, tone, compliance and transit. The techniques for the assessment of gastrointestinal motility are multiple and all have their advantages and disadvantages. In the case of suspected abnormal upper gut transit, gastric and small bowel transit scintigraphy followed by small intestinal (antroduodenojejunalileal) manometry is recommended. Small bowel manometry can identify patterns suggestive of myopathy, neuropathy or obstruction. Information on procedures, indications, significance, pitfalls and guidelines for small bowel manometry is provided in this paper. In this context the potentials of small intestinal manometry for scientific experimental study of neurohumoral agents, such as serotonin receptor agonists and antagonists, on small intestinal motility is presented.

Key words

5-hydroxytryptamine • Enteric nervous system • Gastrointestinal • Hormones • Intestines • Manometry • Motility • Review • Serotonin • Small intestinal manometry

Introduction

Gastrointestinal (GI) motility is an integrated process including myoelectrical activity, contractile activity, tone, compliance and transit. These different entities of motility can be generated and modulated by local and circulating neurohumoral substances. The techniques for the assessment of GI motility and function are multiple. Various manometric techniques are useful tools and among these, small intestinal manometry has, like esophageal and anorectal manometry, gained the status of a diagnostic tool. Small bowel manometry can identify patterns suggestive of myopathy, neuropathy or obstruction. For scientific research purposes small bowel

manometry is excellent for the study of neurohormonal agents. Information on procedures, indications, significance, pitfalls and guidelines for small bowel manometry for these purposes is provided in this paper. In this context, the effects of selective neurohormonal substances, especially serotonin (5-hydroxytryptamine, 5-HT), in health and states of disease is presented.

Methods for measurement of gastrointestinal motility

The methods for measurement of GI motility and the interpretation of recordings are complicated. This warrants standardized procedures and probably computer-

based analysis of recordings. The techniques for the assessment of GI motility and function are multiple and all have their advantages and disadvantages. Radiation (plain abdominal X-ray, with and without contrast and scintigraphy), invasive examinations (manometry, electromyography, barostat and planimetry, intubation and dilution techniques), partial examinations: ultrasonography, computed tomography, photon emission computed tomography (PET), magnetoencephalography, three-dimensional single-photon emission computed tomography (SPECT), magnetic resonance imaging (MRI) and functional-MRI (f-MRI) and finally, indirect assessments (e.g. HIDA bile excretion, paracetamol absorption, ^{13}C -octanoic acid and hydrogen breath tests) (Gregersen and Ehrlein 1993, Husebye 1999, Pallotta *et al.* 1999, Medhus *et al.* 2001, Marciani *et al.* 2001, Schoonjans *et al.* 2002, Gryback *et al.* 2002). All are currently in use, however, mostly for experimental purposes yet. In addition to these *in vivo* methods, several promising *in vitro* methods are available (Lammers *et al.* 2001).

The current tests are generally complementary. The best validated and clinically most significant results pertain to transit tests. Thus, scintigraphy with a standard meal using for example ^{111}In -charcoal in capsules is typically the first test in the evaluation of motor function and often confirms the clinical suspicion of dysmotility. Transit times for solids is about 3 h for the stomach, 3 h for the small intestine, 18 h for the colon, and 6-8 h for the sigmoid and rectum. Scan at 30 min, 1, 2 and 3 h for upper GI transit and 4, 5 and 6 h for lower GI transit is recommended (Bercik *et al.* 2001). Transit times for liquids are slightly less. Considerable intersubject and intrasubject variability should be kept in mind. It is possible to avoid or change the pitfalls of these variabilities. For gastric emptying we can use an intravenous tracer ($^{99\text{m}}\text{Tc}$ -HIDA) which is excreted in the bile and thereby delivered into the duodenum (Gryback *et al.* 2002).

Manometry usually follows transit tests to identify patterns suggestive of myopathy, neuropathy or obstruction but may be most helpful when it shows entirely normal findings, because manometry may partially help to exclude dysmotility as a cause of symptoms. As such, manometric examination of the esophagus is well established to reveal motor activity abnormality (Spechler and Castell 2001). Electrogastrography may identify dysrhythmias, which, however, may be independent of impaired emptying among dyspeptic patients (Camilleri *et al.* 1998).

Functional-MRI seems to be a promising modality for testing the motility as it is able to measure accommodation, wall motion and emptying at the same time (Feinle *et al.* 1999, Bilecen *et al.* 2000). However, limitations of MRI are movement, intraluminal contents, claustrophobia and availability. Other new promising methods include SPECT to measure total and regional gastric volumes (Samsom *et al.* 2000), and ultrasonography together with polyethyleneglycol to visualize the small intestine (Pallotta *et al.* 1999). Investigation modalities of colonic motility have been restricted to transit studies. However, colonic electromyography and manometry has recently been introduced, although only in an experimental set-up yet (Spencer 2001).

In case of suspected abnormal upper gut transit, gastric and small bowel transit scintigraphy followed by small bowel (antroduodenojejunal) manometry is recommended. For abnormal manometry findings suggesting neuropathy, additional tests for autonomic reflexes, CT chest and MRI head is recommended. Findings that suggest a neuropathic disorder are followed by a histological diagnosis of abnormalities (e.g. fibrosis). This can be achieved following Masson's staining of the myenteric plexus. Especially pseudo-obstruction syndromes can be diagnosed by these methods. However, little is known about the specific neurotransmitter disturbances in neuropathy dysmotility. Full-thickness biopsy during a diagnostic laparoscopic procedure might be a future option for conclusive diagnose (Camilleri 2000).

Table 1. Qualitative and quantitative data obtained by small intestinal manometry in health and disease (adapted from Fich *et al.* 1989, Small *et al.* 1997, Camilleri *et al.* 1998, Husebye 1999, Sarna *et al.* 2000).

Amplitude of contractions
Area under the curve
Bursts during fasting
Discrete cluster contractions
Giant migrating contractions
Motility index
Phase I-III incidence
Phasic contractions
Prolonged contractions
Propagation velocity
Retrograde giant contractions
Sustained uncoordinated pressure activity

Information on procedures, indications, significance, pitfalls and guidelines for all these different motility tests, is provided in a recently published paper (Camilleri *et al.* 1998). Further reviewing is not given here, except for small intestinal manometry, as it provides simple and safe data and has great potentials for clinics and the study of neurohumoral agents on intestinal motility.

Small bowel manometry in health

Manometry provides a standard technique for recording detailed small bowel motility patterns in humans. Manometry is a well tolerated, but still an invasive test. Usually a stationary pneumohydraulic system is used with a water-perfused catheter. Recordings of antroduodenojejunoileal intraluminal pressures are performed using a multi-lumen polyvinyl catheter, which

detects pressures resulting from phasic contraction of the circular muscle layer. Information on tonic contractions and longitudinal muscle layer is, however, not sufficiently detected by manometry (Gregersen *et al.* 1992, Husebye 1999). The probe is introduced via the mouth and positioned under fluoroscopic control in such a way that the different sensors are located in the antrum of the stomach and in different regions of the small intestine. The catheter is continuously perfused with water by means of an infusion pump at a low rate and connected to external pressure transducers and recorded at a sampling frequency not less than 4 Hz, for later analysis of motor patterns. A prolonged ambulatory set-up can also be employed and also provides valid and reproducible measures of contractile and propagate activity, especially nocturnally (Widmer *et al.* 1994, Camilleri *et al.* 1998, Husebye 1999, Bortolotti *et al.* 2000, Penning *et al.* 2001).

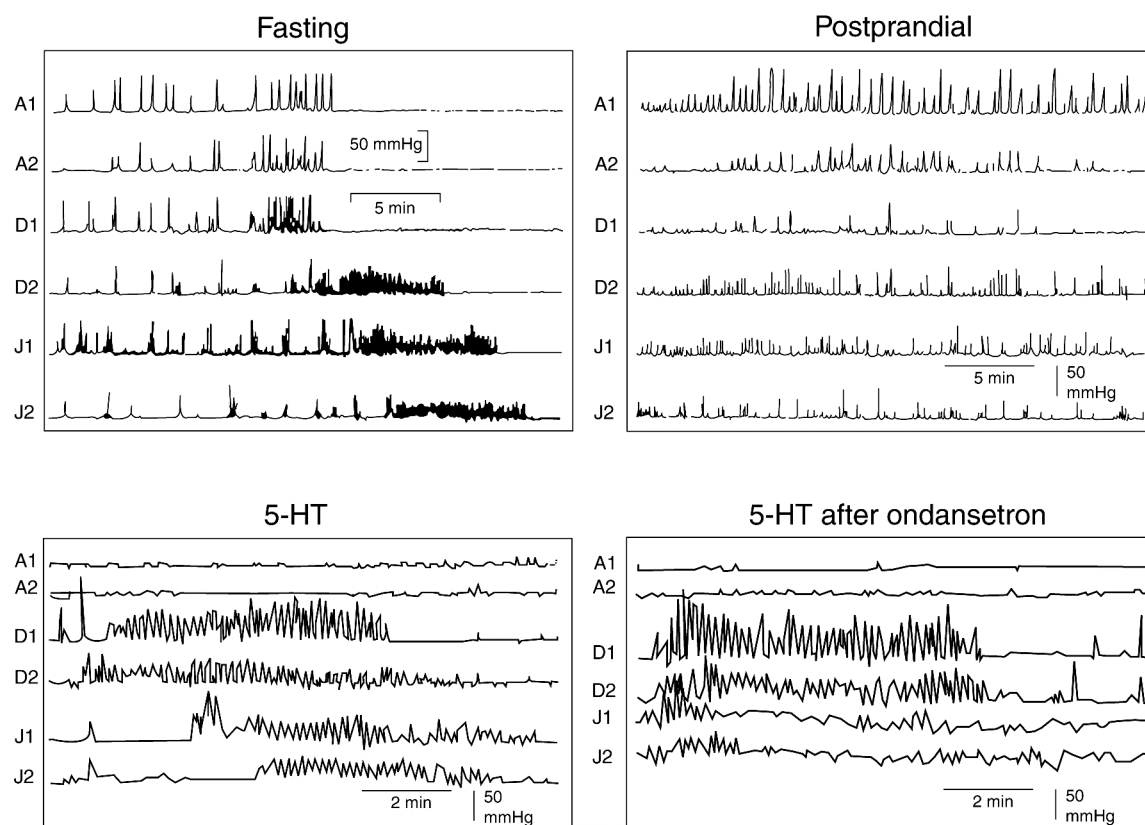


Fig. 1. Small intestinal manometry. Intraluminal pressure recordings from the antroduodenojejunum of a healthy female aged 40 years is shown. Top left shows phase I, phase II, and phase III of the fasting cycle. Top right shows the postprandial pattern with sporadic contractions. Bottom left shows normal propagating phase III of 5-HT (10 $\mu\text{g}/\text{kg}/\text{min}$ intravenous) stimulation. Bottom right shows fast “non-propagating” phase III of 5-HT (10 $\mu\text{g}/\text{kg}/\text{min}$ intravenous) stimulation pretreated with ondansetron (250 $\mu\text{g}/\text{kg}$ intravenous). Unpublished observations.

Under physiologic conditions, the motility of the small intestine is characterized by organized motor

patterns (i.e. pressure waves) in the postprandial and fasting period. The motility index is a cumulative

estimate of the duration, amplitude, propagation distance, length and velocity of contractions (Fig. 1). Several specialized patterns occur during these periods infrequently during health but are more common in pathologic conditions (Table 1). The migrating motor complex (MMC) is the fasting motility complex that was clearly identified by Szurszewski (1969). The MMC

develops before birth and persists in stable fashion throughout life. The MMC cleanse the stomach and small intestine and has as such been termed the gut "housekeeper". In humans, and other intermittent feeders, the MMC consists of at least three distinct phases with a combined total average duration of about 100 min (50-180 min) (Table 2).

Table 2. Small intestinal manometric motility patterns in health and disease. Phase I-III activity in fasting and postprandial conditions. Possible mechanisms are presented (adapted from Camilleri *et al.* 1998, Fich *et al.* 1989, Small *et al.* 1997, Stanghellini *et al.* 1998, Husebye 1999, Quigley 1999a,b, Kellow *et al.* 1999, Sarna *et al.* 2000).

<u>In health</u>		
Fasting condition		
Phase I	Period of silence. Defined as less than 3 pressure waves/10 min. Follows a phase III.	
Phase II	Period of uncoordinated contractions. Defined by amplitude, duration, propagation distance and velocity of single contractions, and cumulative motility index	
Phase III	Period of coordinated contractions. Defined as regular rhythmic contractions at high frequency, lasting from 2-15 min and migrating aborally. Propagation velocity and maximal frequency decrease while duration increases aborally	
Postprandial condition		
Loss of cycling activity		
<u>In disease</u>		
Fasting condition		
Phase I	Absent	?
Phase II	Absent	Extrinsic neuropathy
	Bursts, sustained contractions	Intrinsic neuropathy
	Discrete clustered contractions	IBS, mechanical subocclusion
	Giant contractions	Mechanical subocclusion, IBS and diarrhea
Phase III	Absence	Intrinsic neuropathy
	Abnormal conformation and/or propagation	Intrinsic neuropathy
Postprandial condition		
	MMC returns within 180 min	Extrinsic neuropathy
	Bursts, sustained contractions	Intrinsic neuropathy
	Discrete clustered contractions	Mechanical subocclusion, IBS, and slow transit constipation.
	Giant contractions	Mechanical subocclusion

Phase I is a period of motor quiescence that lasts for approximately 60 % of the total cycle length. Phase II, which represents about 30 % of the cycle length is a period of increasing but irregular contractions. Phase III is the hallmark of the fasting condition and reflects the neuromuscular function. It is one 5-10 min period of

intense, rhythmic contractions that begin in the gastric body and propagate unimpeded to the pylorus, with complete obliteration of the antral lumen. The duration of phase III increases slowly down through the small intestines, from about 5 min in the duodenum to 10 min in the ileum. The propagation velocity also varies, with

about 10 cm/min in the duodenum, 7 cm/min in the proximal jejunum and about 1 cm/min in the distal ileum. Most phase III complexes originate in the gastroduodenal region, but as many as one third of them begin distal to the ligament of Treitz. The terminal pressure waves of phase III in the proximal duodenum are mainly retroperistaltic (Castedal and Abrahamsson 2001, Castedal *et al.* 1997). An additional phase IV, which is a brief period of transitional motor activity from the intense phase III to the quiescence of phase I, has been observed. As one phase III is reaching the terminal ileum, a nascent phase III is developing in the proximal gut. Only one half of them propagate from beyond the middle jejunum, and

only 10 % reach the distal ileum. Average amplitude is 20-40 mmHg for phase III. Single wave amplitude and duration reflects more the myogenic component than the neurogenic component. In addition to the MMC, discrete clustered contractions (DCC, pressure waves at slow wave frequency, 1-2 per minute) and isolated bursts are seen in health. They occur mostly in the jejunum, however, their physiological significance remains unknown. Finally, one has to remember the large intra- and interspecies variations in especially motility period's (Husebye 1999) and the diurnal variation in response to various stimuli (Gschossmann *et al.* 2001).

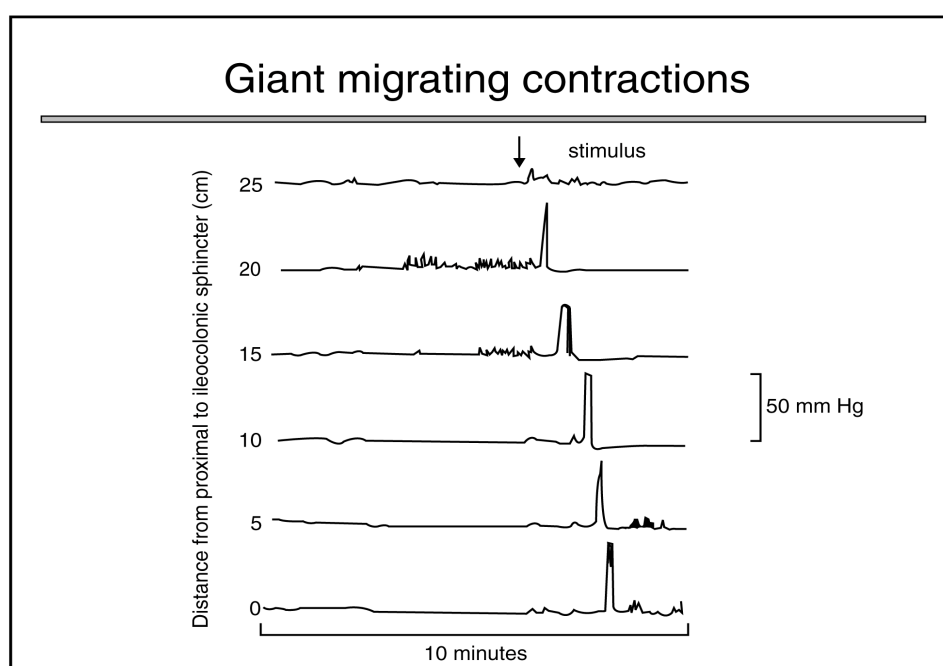


Fig. 2. Propagation of high amplitude contractions (giant migrating contractions, GMC). Schematic representation of intraluminal pressures (manometric recordings) from the ileum following intraluminal stimulation with for example short-chain fatty acids.

The propulsive characteristics vary depending on the phases of the MMC, phase III being the main propagate period. A normal phasic contraction is defined as less than 10 mmHg in amplitude. Ultrapropulsive contractions exist: giant migrating contractions (GMC, 1 cm/sec, >10 s with an amplitude >30 mmHg) (Fig. 2) and similar retrograde giant contractions (RGC, 10 cm/s). The GMC occurs primarily in the ileum and is associated with the symptoms of diarrhea and abdominal cramping. They propagate uninterruptedly and rapidly for long distances in the caudal direction in the small intestine and colon. The RGCs propagate rapidly in the oral direction

in the upper small intestine and up to the antrum only. These contractions are much larger in amplitude (2-3 x) and longer in duration (4-6 x) than the phasic contractions. Because of their large amplitude, they strongly occlude the lumen. Strong occlusion of the lumen and long distances of propagation makes these contractions highly effective in propulsion. The GMCs and RGCs are not regulated by slow waves and the mechanisms of regulation of these contractions are not fully understood yet (Castedal *et al.* 1997). However, it seems that substance P (SP) acts directly on smooth muscle cells and stimulates GMCs, that produce the

sensation of abdominal discomfort and cramping. Normally, GMCs occur once or twice per day in the terminal ileum and proximal colon (Sarna *et al.* 2000).

The postprandial pattern is induced 5 to 10 min after ingestion of a meal, peaks after 10 to 20 min, and persists as long as food remains in the stomach. The length of the fed motor period is proportional to the number of calories consumed, with fats inducing a more prolonged fed pattern than proteins or carbohydrates. For 630, 1260 and 2520 kJ meals, the postprandial period are

3, 6 and 7 h, respectively (Ouyang 1989, Husebye 1999). The myoelectric pattern of a meal consists of random bursts of spike potentials, with the motor findings of contractions of variable amplitude superimposed on small changes in tone. About 50 % of contractions in the fed state do not propagate (Husebye 1999). A summary of data, which can be obtained and described for small intestinal manometry in the interdigestive and the postprandial period, is presented in Tables 1, 2 and 3.

Table 3. Etiology of small intestinal dysmotility. Primary and secondary causes as well as myopathies and neuropathies are presented (adapted from Quigley 1999a,b, Husebye 1999, Thomson *et al.* 2001).

Primary causes

1. Familiar types: Familial visceral myopathies and neuropathies and childhood visceral myopathies
2. Nonfamiliar types: Visceral myopathies or neuropathies

Secondary causes

1. Endocrine disorders: diabetes mellitus, thyroid disease, hypoparathyroidism and carcinoids
2. Miscellaneous: celiac disease, diverticulosis, radiation enteritis, lymphoid infiltration, postgastrointestinal infection, anorexia nervosa
3. Myopathies: collagen diseases, muscular dystrophies and amyloidosis, advanced scleroderma, dermatomyositis
4. Neuropathies: Chagas's disease, ganglioneuromatosis, carcinomatosis, Parkinson's disease, spinal cord injury, early scleroderma, neurofibromatosis and multiple sclerosis
5. Pharmacologic agents: phenothiazines, tricyclic antidepressants, antiparkinsonian medications, ganglionic blockers, narcotics including morphine

Myo- and neuropathies to small intestinal dysmotility

	Primary	Secondary
Myopathy	Familial and sporadic	Dystrophia myotonica Progressive muscular dystrophy
Neuromyopathy	Sporadic	Amyloidosis Dermatomyositis Jejunal diverticula Systemic sclerosis
Intrinsic neuropathy	Familial and sporadic	Chronic pseudoobstruction Chagas disease Hirschsprung's disease Viral infections Von Recklinghausen's disease
Extrinsic neuropathy		Brain diseases Chronic autonomic neuropathy Diabetic autonomic neuropathy Spinal cord injury

The intestinal MMC is not an isolated phenomenon. It cycles in phase with contractile activity

of the gallbladder and the sphincter of Oddi and gut secretions, suggesting that the intestinal MMC is only a

part of a larger cycling phenomenon involving visceral and solid organs in the upper abdomen. For example bile release into the duodenum cycles in phase with duodenal phase III activity. Certainly, the enterohepatic circulation seems important for MMC activity as endogenous bile seems to be a physiologic stimulant of phase II complexes through induction of motilin release. The subsequent release of cholecystokinin (CCK) produces exaggerated high-amplitude ileal contractions (Torrents *et al.* 2001). There is also evidence for an interaction and strong integration between interdigestive motility and mucosal secretion, regulated by the submucous ganglia. As such, most segments induce secretion in the late phase II of the MMC (Mellander 1996). Discrete clusters seem particularly potent stimulators for activation of mucosal secretion (Mellander *et al.* 2000). The interaction between blood flow and motility has been evaluated and the local mesenteric blood flow oscillates during a MMC cycle. However, changing the blood flow does not affect contractility (Cowles *et al.* 1999). Finally, artifacts could be present in manometric signals. For example recordings from the horizontal part of the duodenum could result from compression by the superior mesenteric artery (Schwartz *et al.* 2001).

The neurohumoral regulation of the MMC is complex and only partly understood. Intrinsic innervation, including a preserved enteric nervous system, is essential for the fasting condition, while extrinsic innervation seems essential for the postprandial response. It is likely, that several hormones act in concert with the enteric and extrinsic innervation of the gut to induce the fed state (Husebye 1999). Mental stress reduces the recurrence of phase III, while sleep increases phase I activity at the expense of phase II, underlining the importance of extrinsic modulation from the CNS on MMC activity (Husebye 1999). Most intrinsic nerves regulating MMC propagation reside in the myenteric plexus. However, the deep muscular plexus and submucous plexus have also some role in maintenance of the MMC (Hasler 1995).

Several hormones and neurotransmitters induce MMC activity with premature small intestinal phase III activity, including motilin and motilin receptor analogues (e.g. erythromycin), somatostatin, opioids, SP, dopamine, some prostaglandins (PGs), epidermal growth factor, histamine H₁ receptor agonists and 5-HT. Others inhibit MMC activity and induce complexes similar to the fed pattern, including CCK, insulin, glucagon, neurotensin, neuromedin, nitric oxide (NO), gamma aminobutyric acid (GABA), bombesin, enkephalins and prostaglandin E₂

(PGE₂). Further substances, such as gastrin, dopamine, peptide YY (PYY), bradykinins and galanin have either stimulatory or inhibitory effects, dependent on species and region (Husebye 1999).

Motilin seems to be a key initiator of MMC cycles that begin in the stomach, but not for those beginning in the small intestine, which seem to be regulated by input from enteric and extrinsic neurons (Husebye 1999). Motilin does not seem to play a role in the fed state. In addition to motilin, the only peptides known to cycle in phase with the MMC activity are somatostatin and **pancreatic polypeptide (PP)**. In the upper part of the small intestine somatostatin seems to be inhibitory, whereas in the middle part, phase III of MMC is stimulated in dog and man, but not in rats, where somatostatin is inhibitory. Somatostatin delays contraction and transit as a result of its ability to decrease propagation *via* a mechanism involving nitrergic transmission and sst2 receptors (Abdu *et al.* 2001, Nehra *et al.* 2001). Octreotide, a somatostatin synthetic analogue, increases the frequency of MMC by shortening the duration of phase II (Anuras and Hodges 1995) and is sometimes of benefit for patients with intestinal pseudoobstruction and bacterial overgrowth (Kuemmerle 2000, Bassotti *et al.* 1997). No evidence has been established for **PP** to be a mediator of the MMC. **Opioids** are well known to suppress motility. They enhance the amplitude of nonpropulsive small bowel contractions but decrease propulsive contractions. The jejunum is more prone to these effects than the ileum. Stimulation of the **α₂-adrenoreceptor** has prominent but diverse effects on the regularity of the MMC. In humans, clonidine has the ability to stimulate the appearance of phase III, but substantial species differences exist (e.g. rat), suggesting different mechanisms for the control of MMC. Also β-adrenoreceptors are of importance for the regulation of MMC, as the non-selective β-adrenoreceptor agonist, isoprenaline, is able to replace the recycling MMC by irregular spiking in the small intestine of humans. Peripherally acting **muscarinic M₂ receptor** agonists, e.g. the anticholinesterase neostigmin, has been shown to stimulate irregular clustered contractions. However, the common M-receptor blocking agents (e.g. atropine) as well as the **ganglionic nicotinic receptor** blocker agent, hexamethonium, generally inhibits the propagation of the MMC and activity in the antroduodenojejunal region (Katschinski *et al.* 1995, Torrents *et al.* 2001). However, regional and/or species differences seem to exist as atropine has been shown to induce phase III MMC activity in the ileum of dogs (Borody *et al.* 1995). The

tachykinins also regulate gut motility and MMC activity in a NO-sensitive manner (Schmidt *et al.* 2002). Data from experiments in rat and man indicate that SP and neurokinin A (NKA) stimulate motor activity in such a fashion that the MMC is abolished and irregular spiking or contraction with a phase II-like pattern is induced. The same result is obtained with neurokinin B mediated via a cholinergic link. In accordance NK₁ and NK₂ receptor antagonists inhibits the digestive phase III contractions (Tohara *et al.* 2000) and NK₂ receptor antagonists inhibits NKA-induced small intestinal MMC activity (Lordal *et al.* 2001). Finally, inhibition of NO biosynthesis by N^G-monomethyl-L-arginine, triggers the onset of a fast propagating phase III and shortens the postprandial period, indicating that NO is involved in the modulation of fasting and postprandial small intestinal motility in humans (Kuiken *et al.* 2002).

Serotonin (5-HT) is predominantly excitatory in the small intestine, increasing the contraction rate, prolonging the length of spread of duodenal contraction waves after a meal and converting mixing motor patterns to propulsive ones. Rats treated with 5,6- or 5,7-dihydroxytryptamine are ablated for myenteric 5-HT neurons. This results in MMC disruption, prolongation of MMC periodicity, and decreased contractile propagation velocities. Antagonism at the 5-HT₃ receptor subtype inhibits phase III activity, without affecting plasma motilin levels, evidencing blockade of motilin-induced responses rather than diminution of motilin release. Blockade of 5-HT₄ receptors appear to be the dominating inhibitory mechanism for the MMC, with 5-HT₃ receptors being slightly less important, and M receptors of even less importance for the inhibition of fasting gut motility, at least in rat small intestine (Axelsson *et al.* 2001). These results suggest that 5-HT may play a significant physiologic stimulatory role in the modulation of small intestine motor activity. It is likely that also secretin, gastrin, CCK, insulin, PYY, neuropeptide Y (NPY), neurotensin, NO and glucose-dependent insulinotropic polypeptide (GIP, previously known as gastric inhibitory peptide) are involved in the postprandial pattern, as blood concentrations of these substances increase after a meal (Husebye 1999).

The CNS has profound effects on fasting and postprandial MMC activity via the brain-gut axis. Intracerebroventricular administration of CCK and corticotropin-releasing hormone (CRF) decreases, while somatostatin, calcitonin, calcitonin gene-related peptide (CGRP), neurotensin, NPY, thyrotropin-releasing hormone (TRH) and opioids increases fasting MMC

activity, while galanin restores fasting MMC activity and atropine and SP shortens the postprandial pattern (Hasler 1995).

Small bowel manometry in disease

Specific disease diagnosis cannot be made by manometry alone. However, the functional integrity (i.e. neuromuscular dysfunction) can be evaluated by manometry and used as predictor of response to enteral nutrition and medical therapy (Stanghellini *et al.* 2000, Miedema *et al.* 2001). Investigation with small bowel manometry is warranted for patients suspected of the pseudoobstruction syndrome and for patients in whom a total colectomy is considered because of intractable constipation (Smout 2001). Furthermore, as a consequence of the close physiological and clinical relationship between the MMC and the motility of the stomach and small intestine, as well as the GMC complexes in the colon, pharmacological control of the MMC and GMC have and will be attempted in the clinical setting (Husebye 1999, Martin *et al.* 2001).

Small bowel manometry can distinguish between neuropathic and myopathic disorders (Tables 2 and 3). In neuropathy, there is a loss of inhibitory motor neurons and intraluminal pressures are uncoordinated but with normal or even increased amplitude. In myopathy there are co-ordinated low amplitude pressures (<10 mm Hg) activities in early and mild stages and complete absence of contractions in advanced stages of chronic intestinal pseudoobstruction (CIP) (Stanghellini and Corinaldesi 1988). Other findings indicating neuropathy includes aberrant configuration, propagation of phase III of the interdigestive MMC, abnormal MMC response to 5-HT, bursts of phasic pressure activity and abnormal or absent conversion to a fed pattern after meal ingestion with preservation of normal amplitude contractions. Several other conditions than CIP are associated with motility disorders of the small intestine and can be discovered by small bowel manometry, although some of them are somewhat controversial. For patients with myopathy, manometry demonstrates a decrease in frequency and amplitude of contractions of the affected segment in both fed and fasting states. This has clinical implications, as myopathy indicates poor response to enteric feeding. In addition to disorganization and incoordination of motor activity, the MMC is often absent or abnormal in disorders of neuropathy (Quigley 1999ab, Husebye 1999). A summary of putative indications for small bowel manometry in the clinics is presented in Table 4.

Table 4. Indications for small bowel manometry in the clinics (adapted from Camilleri *et al.* 1997, Seidel *et al.* 1999, Quigley 1996, Quigley *et al.* 1997, Quigley 1999a, 1999b, Husebye 1999).

Abdominal distension
Abdominal pain
Before surgery for constipation
Chronic constipation
Chronic intestinal pseudoobstruction
Confirmation of the presence and extension of generalized disease
Extrinsic neuropathies suspected (e.g. DM and sclerosis)
Food hypersensitivity
Functional dyspepsia
Irritable bowel syndrome
Intractable constipation
Intrinsic neuropathies suspected (viral infection)
Mesenteric ischemia
Myopathies
Nausea
Neuropathies
Organic obstruction.
Postsurgical syndromes
Postvagotomy syndrom
Recurrent episodes of subocclusion
Suspicion of mechanical obstruction (e.g. adhesions).
Suspicion of diabetic gastroenteropathy
Those with abnormal gastric motility who failed regular treatment with prokinetics
Vomiting

Motor patterns which should be recognized since they usually bear clinical pathological significance includes: propagated contractions, ultra-rapid contractions, propagated clustered contractions, bursts of contraction, hypocontractility indicating myopathy, while hypercontractility (bursts and sustained uncoordinated pressure activity) and a failure of development of the fed response indicates neuropathy (Kellow *et al.* 1999). In the following, motor patterns and transit time findings for mainly the small intestine in some disease states is presented.

Achalasia. Manometry in achalasia patients reveals that the loss of inhibitory motor neurons to smooth muscle cells resulting in dysmotility and abnormal pattern in both the fasting and postprandial states. They have hypomotility in the fasting state and have abnormal

repetitive retrograde contractions in the postprandial state (Stanghellini *et al.* 1998, Schmidt *et al.* 1999).

Bacterial overgrowth. Bloating, pain and diarrhea results from this condition and is usually a result of abnormal motility. In manometry, hypomotility with rare phase III activity, weak and disorganized contractions, are observed (Husebye 1999).

Cholecystectomy. A relationship between gallbladder function and gut motility is likely (Qvist *et al.* 1995, Qvist 1995). Patients with symptomatic gallbladder stones have a prolonged orocecal transit time of a liquid meal following cholecystectomy (Penagini *et al.* 1988). The location of prolonged transit is not known. However, it does not seem to be the duodenum, as the manometric motility patterns in the duodenum are not changed following cholecystectomy (Andersen *et al.* 1999). Thus gastric, jejunal and/or ileal dysmotility is likely, which might explain some symptoms of the postcholecystectomy syndrome.

Constipation. The frequency of GMCs is significantly reduced or totally absent in idiopathic chronic constipation (Sarna *et al.* 2000). Large bowel dysmotility is largely present in idiopathic and slow-transit constipation, represented by a reduced number of high-amplitude propagated contractions (HAPC) in the colon. A reduced number of HAPCs is also secondary to antidepressant drugs and responsible for constipation in these patients (Bassotti 2000). Another abnormal finding are intense single contractile waves called individual migrating contractions, which may be seen during the fed period. These have amplitudes twice those of normal fed phasic contractions. They, unlike GMCs, occur predominantly in the proximal small intestine and are associated with intestinal slow wave disruption (i.e. dysmyogenesis or amyogenesis). They are atropine- and hexamethonium-sensitive, suggesting cholinergic pathways involving ganglia. Some patients with slow-transit constipation have abnormal antroduodenal manometric findings, such as DCC present in the fasting period and burst of uncoordinated contractions present in both fasting and after feeding (Glia and Lindberg 1998).

Depression. In endogenous mental depression small intestinal phase III cycles are reduced. Similarly, stressful stimulation can disrupt fasting motor activity and suppress phase II activity and DCCs. For most part, stress-induced effects on small bowel motility are associated with delayed small bowel transit (Hasler 1995).

Functional dyspepsia. Sensorimotor dysfunction in the stomach or small intestine is present in some patients

with functional dyspepsia. They have frequent interdigestive and postprandial antral dysmotility and abnormal MMC activity. Abnormalities in the small intestine include alterations of periodicity of MMC, the absent or aberrant propagation of phase III, significantly more frequent bursts, clustered contractions, and prolonged propagated contractions, a longer duration of phase II and an abnormal postprandial motor response. Contraction frequency is higher in diarrhea-predominant-irritable bowel syndrome (D-IBS), while contraction amplitude is lower in constipation-predominant irritable bowel syndrome (C-IBS). However, IBS patients usually have preserved nocturnal MMC, which emphasizes the importance of the brain-gut axis in IBS (Husebye 1999, Kellow *et al.* 1999, Quigley *et al.* 1997).

Hormone overproduction syndromes. In Zollinger-Ellison's syndrome, increased gastric emptying is present, while in hyperthyroidism and the carcinoid syndrome, accelerated small intestinal transit and premature duodenal phase III activity is observed (der Ohe *et al.* 1993).

Inflammation and infection. In these conditions, the frequency of GMC may be increased to as much as one per hour. These changes are reduced by nonspecific 5-HT antagonists and mast cell stabilizers (Sarna *et al.* 2000).

Irradiation can cause dysmotility and likely diarrhea by disrupting the MMC by inducing high-amplitude contractions. These changes may in part result from altered enteric nervous system activity or abnormal release of gut endocrine peptides such as SP and neurotensin, as the afferent nerves are implicated in radiation-induced intestinal peptide release. Abnormal motility and gram-negative bacilli in the proximal small intestine are essential factors in the pathogenesis of severe late radiation enteropathy, whereas hypochlorhydria facilitates unspecific gastric colonization and thereby probably also dysmotility of the stomach (Husebye *et al.* 1995, Fraser *et al.* 1998, Picard *et al.* 2001).

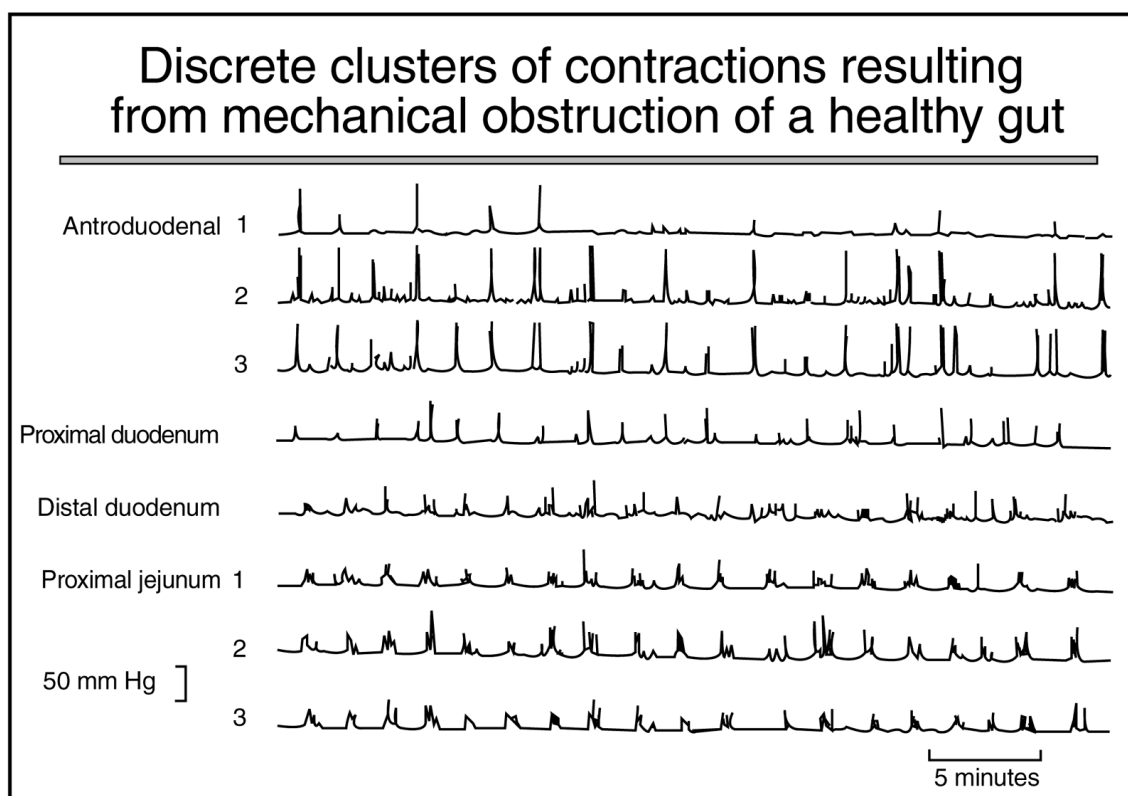


Fig. 3. Schematic intraluminal pressures (manometric recordings) from antroduodenojejunum of a healthy gut with mechanical obstruction of the small intestine. Note the clustered contractions. Retrograde peristaltic contractions, GMCs, and nonpropagated prolonged contractions (>20 s) are not seen in these traces.

Mechanical obstruction pattern can be detected as clustered contractions (Fig. 3) in conjunction with periods of intervening quiescence lasting long (>1 min) and retrograde peristaltic contractions (RPC), which are most often associated with retching or vomiting. RPC migrate very rapidly, up to 10 cm/s over long distances (Quigley 1999a). GMC and nonpropagated prolonged contractions (>20 s) are pathological findings in the upper small intestine, indicating a cleaning process of the gut in infectious states or mechanical obstruction, respectively (Husebye 1999). Patients with recurrent subocclusions have a significant higher frequency of abnormal patterns suggestive of a greater derangement of the control mechanisms of gut motility (Cogliandro *et al.* 2000).

Postsurgical syndromes. Laparotomy and traumatic shock is followed by inhibition of gut motility (postoperative/adynamic ileus). Jejunal manometry on postoperative day 1 predicts tube feeding intolerance in the postoperative and posttraumatic period (Miedema *et al.* 2001, Moore *et al.* 2001). The major reason for simple postoperative ileus seems to be an impaired vagal input. Large individual contractile waves that propagate aborally down the long segments of small intestine are seen immediately after laparotomy. Jejunal spiking activity and the phase III of the MMC normally recurs in the proximal bowel within 3 h after major abdominal surgery, such as colectomy, whereas phase II returns as late as 40 h (Husebye 1999). Laparotomy, involving simple manipulation of the small intestine, causes injury, initiating an inflammatory cascade in the small bowel wall, which generates eicosanoids and proinflammatory cytokines, and activation of different neurons (Brehmer *et al.* 2000). Therefore, postoperative ileus involves an immune cell/neuronal interaction. As such, non-selective and selective cyclooxygenase enzyme (COX)-2 inhibitors ameliorate postoperative small bowel ileus, at least in rodents (Josephs *et al.* 1999). Furthermore, 5-HT₄ receptor agonists and NK₂ receptor antagonists shorten the duration of motor inhibition and induce premature recovery of phase III of the MMC. This mechanism is probably due to effects on the afferent fibres (Zittel *et al.* 2000, Toulouse *et al.* 2001). Laparotomy with bowel resection causes prolonged postoperative ileus and usually varying kinds of permanent dysmotility. An altered gastric and small intestinal motility is frequently seen in symptomatic patients following antireflux surgery and gastric surgery (e.g. Roux stasis syndrome) (Hasler 1995). The duration of the interdigestive motor complex

is shorter, while gastric emptying is not changed, following extensive resections of the ileum (Remington *et al.* 1983). Disruption of the neurohumoral control and especially gut reflexes cause these abnormalities. For example, CCK and 5-HT are released in increased amounts following gastrectomy, supporting the role of 5-HT to contribute to the reflex inhibition of intestinal motility causing the postoperative ileus. As such, tropisetron (a 5-HT₃ receptor antagonist with 5-HT₄ receptor agonist properties in high doses) improves postoperative colonic motility in those, who underwent colonic resection, probably due to decreased sensitivity to released 5-HT (Kreis *et al.* 2001). Thus 5-HT₄ receptor agonists, 5-HT₃ and NK₂ receptor antagonists and COX-2 inhibitors are promising therapeutic tools for postsurgical intestinal atony (Quigley 1996, Quigley *et al.* 1997, Seidel *et al.* 1999).

Intestinal resection. The postprandial intestinal motor pattern is prolonged with antral hypomotility and reduced gallbladder contraction, while the interdigestive motor pattern is characterized by increased MMC cycling frequency, in patients after colectomy with pouch reconstruction (Brown *et al.* 1992). Following transection of the small bowel and reanastomosis, neuronal growth across the anastomoses occurs at 28 days, co-ordinated cycling begins at 45 days and complete recovery occurs within 100 days, suggesting that enteric nerves have the capability to regenerate severed connections. If a segment of colonic wall is interposed between small intestine segments or if intestinal anastomoses are performed in end-to-side or side-to-side fashion, co-ordination does not resume even after 180 days, suggesting the need for anatomic continuity of small intestine-type enteric nerves. Immediately after transection and reanastomosis of the small intestine, VIP, gastrin releasing polypeptide (GRP) and somatostatin are decreased distal to the anastomoses. Recovery of MMC cycling is associated with recovery of these transmitters and evidence of nerve regrowth, suggesting that peptidergic nerves within the myenteric plexus may contribute to co-ordinate MMC activity (Hasler 1995).

Endotoxemia. Inflammatory bowel disease causes gut dysmotility. In animals, bacterial lipopolysaccharide (LPS) induced-endotoxemia causes activation and influx of inflammatory cells into the muscle tissue and thereby delays gastric emptying (Cullen *et al.* 1995). The effect of LPS on gut motility seems biphasic with an initial acceleration in transit and motility followed by a delayed

effect. The initial phase is likely depended on interleukin- 1β , and the second phase likely depends on tumor necrozing factor- α (Ceregrzyn *et al.* 2001). These effects can be reduced by a variety of neurohormonal substances, even with rare substances such as the submandibular gland peptide-T in rats (Mathison *et al.* 2001).

The vast majority of studies do not support the hypothesis that *Helicobacter pylori* (HP) influence gut motility (Manes and Malfertheiner 1999). However, HP has been shown to cause some functional and morphological changes in stomach, resulting in delayed gastric emptying in mice (Bercik *et al.* 2001). Colonic transit is often accelerated for patients with portal hypertension, whereas the motor function of the stomach and the small intestine is unaffected (Madsen *et al.* 2000). Large individual contractile waves that propagate aborally down the long segments of small intestine are seen during hypoxia, anemia and gangrene or immediately after death (Husebye 1999). The intestinal anaphylaxis is associated with MMC disruption, which are reduced by the 5-HT receptor antagonist methysergide and the COX inhibitor, indomethacin (Hasler 1995). Finally, clustered contractions are often present both in the fasting and postprandial state of pseudoobstruction (Soffer and Thongsawat 1996, Cucchiara *et al.* 1994, Cucchiara *et al.* 2000, Marie *et al.* 1998, Smout 2001).

References

- ABDU F, HICKS G, ALLEN JP, GRUNDY D: Characterization of somatostatin receptor mediated inhibition of small intestinal peristalsis in rat and mouse. *Gastroenterology* **118**: A303, 2001.
- ANDERSEN PV, MORTENSEN J, OSTER-JORGENSEN E, RASMUSSEN L, PEDERSEN SA, QVIST A: Cholecystectomy in patients with normal gallbladder function did not alter characteristics in duodenal motility which was not correlated to size of bile acid pool. *Dig Dis Sci* **44**: 2443-2448, 1999.
- ANURAS S, HODGES D: Dysmotility of the small intestine. In: *Textbook of Gastroenterology*. YAMADA T (ed), Philadelphia, JB Lippincott, 1995, pp 1577-1605.
- AXELSSON L-G, GILLBERG P-G, HELLSTROM PM: Predominant inhibitory effect of 5-HT₃ and 5-HT₄ receptor antagonist, compared to muscarinic antagonists, on the migrating motor complex in the rat. *Gastroenterology* **120** : A171, 2001.
- BASSOTTI G: Motions and emotions: the treatment of depression causes constipation. *Neurogastroenterol Motil* **12**: 113-115, 2000.
- BASSOTTI G, GERMANI U, CALCARA C, SPINOZZI F, ROSELLI P, MORELLI A: Effects of octreotide on manometric variables in patients with neuropathic abnormalities of the small bowel. *Dig Dis Sci* **42**: 1634-1639, 1997.

Concluding remarks and perspectives

The use of small bowel manometry has now been established as a first-choice experimental method for physiological and pharmacological study of functional integrity (neuromuscular function) of the upper gastrointestinal tract. Furthermore small bowel manometry should be employed in the clinics for the identification of states of myopathy, neuropathy or obstruction. A prediction of response to enteral nutrition and medical therapy can be made. However, specific disease diagnosis cannot be made by manometry alone. Conditions with fasting and stimulation with a standard meal and neurohormonal substances, such as motilin analogues (e.g. erythromycin) or serotonin, should be employed.

Acknowledgements

This work was kindly supported by Sofus Carl Emil Friis and his wife Olga Friis Foundation, The Carlsberg Foundation, The Enid Ingemann Foundation, Else and Mogens Wedell-Wedellsborg Foundation, Dagmar Marshall Foundation, The Lundbeck Foundation, The Novo Nordisk Foundation, C.C. Klestrup and his wife Henriette Klestrup Foundation, The Danish Medical Association Research Foundation and the Danish Hospital Foundation for Medical Research in Region of Copenhagen, The Faeroe Islands and Greenland. I thank Novartis Healthcare A/S, Denmark, for support and help on illustrations.

- BERCIK P, DE GIORGIO R, WANG L, VERDU EF, BARBARA G, BLENNER-HASSETT, TOUGAS G, COLLINS SM: Neural changes during chronic H. pylori (Hp) infection in mice: role of the immune system. *Neurogastroenterol Motil* **13**: 374, 2001.
- BILECEN D, SCHEFFLER K, SEIFRITZ E, BONGARTZ G, STEINBRICH W: Hydro-MRI for the visualization of gastric wall motility using RARE magnetic resonance imaging sequences. *Abdom Imaging* **25**: 30-34, 2000.
- BORODY TJ, CLARK IW, ANDREWS P, HUGH TB, SHORTIS NP: Eradication of Helicobacter pylori may not reverse severe gastric dysplasia. *Am J Gastroenterol* **90**: 498-499, 1995.
- BORTOLOTTI M, ANNESE V, COCCIA G: Twenty-four hour ambulatory antroduodenal manometry in normal subjects (co-operative study). *Neurogastroenterol Motil* **12**: 231-238, 2000.
- BREHMER A, GOBEL D, FRIESER M, GRAF M, RADESPIEL-TROGER M, NEUHUBER W: Experimental hypertrophy of myenteric neurones in the pig: a morphometric study. *Neurogastroenterol Motil* **12**: 155-162, 2000.
- BROWN NJ, RUMSEY RD, BOGENTOFT C, READ NW: The effect of adrenoceptor antagonists on the ileal brake mechanism in the rat. *Br J Pharmacol* **105**: 751-755, 1992.
- CAMILLERI M: Abnormalities of enteric and extrinsic nervous system and motility disorders. In: *Falk symposium 112. Neurogastroenterology. From basics to the clinics*. KRAMMER H, SINGER MV (eds), Dordrecht, Kluwer Academic Publishers, 2000, pp 424-440.
- CAMILLERI M, STANGHELLINI V, AZPIROZ F: Small bowel manometry. *Dig Dis Sci* **42**: 2401-2402, 1997.
- CAMILLERI M, HASLER WL, PARKMAN HP, QUIGLEY EM, SOFFER E: Measurement of gastrointestinal motility in the GI laboratory. *Gastroenterology* **115**: 747-762, 1998.
- CASTEDAL M, ABRAHAMSSON H: High-resolution analysis of the duodenal interdigestive phase III in humans. *Neurogastroenterol Motil* **13**: 473-481, 2001.
- CASTEDAL M, BJORNSSON E, ABRAHAMSSON H: Duodenal juxtapyloric retroperistalsis in the interdigestive state in humans. *Scand J Gastroenterol* **32**: 797-804, 1997.
- CEREGRZYN M, KAMATA T, YAJIMA T, KUWAHARA A: Biphasic alterations in gastrointestinal transit following endotoxaemia in mice. *Neurogastroenterol Motil* **13**: 605-613, 2001.
- COGLIANDRO R, STANGHELLINI V, COGLIANDRO L, BARBARA G, DE GIORGIO R, MORSELLI-LABATE AM: Small bowel motor abnormalities in malnourished symptomatic adults complaining of severe digestive symptoms with and without functional subocclusive episodes. *Gastroenterology* **118**: A154, 2000.
- COWLES VE, RYAN RP, SARNA SK: Interaction between blood flow and motility in normal and inflamed ileum. *Neurogastroenterol Motil* **11**: 409-420, 1999.
- CUCCHIARA S, ANNESE V, MINELLA R, FRANCO MT, LERVOLINO C, EMILIANO M, AURICCHIO S: Antroduodenojejunal manometry in the diagnosis of chronic idiopathic intestinal pseudoobstruction in children. *J Pediatr Gastroenterol Nutr* **18**: 294-305, 1994.
- CUCCHIARA S, BORRELLI O, SALVIA G, LULA VD, FECAROTTA S, GAUDIELLO G, BOCCIA G, ANNESE V: A normal gastrointestinal motility excludes chronic intestinal pseudoobstruction in children. *Dig Dis Sci* **45**: 258-264, 2000.
- CULLEN JJ, CAROPRESO DK, EPHGRAVE KS: Effect of endotoxin on canine gastrointestinal motility and transit. *J Surg Res* **58**: 90-95, 1995.
- DER OHE MR, CAMILLERI M, KVOLS LK, THOMFORDE GM: Motor dysfunction of the small bowel and colon in patients with the carcinoid syndrome and diarrhea. *N Engl J Med* **329**: 1073-1078, 1993.
- FEINLE C, KUNZ P, BOESIGER P, FRIED M, SCHWIZER W: Scintigraphic validation of a magnetic resonance imaging method to study gastric emptying of a solid meal in humans. *Gut* **44**: 106-111, 1999.
- FICH A, PHILLIPS SF, HANSON RB, ZINSMEISTER AR: Rapid frequency rhythmic postprandial motility in the canine ileum. *Am J Physiol* **257**: G766-G772, 1989.
- FRASER R, FRISBY C, BLACKSHAW LA, SCHIRMER M, HOWARTH G, YEOH E: Small intestinal dysmotility following abdominal irradiation in the rat small intestine. *Neurogastroenterol Motil* **10**: 413-419, 1998.
- GLIA A and LINDBERG G: Antroduodenal manometry findings in patients with slow-transit constipation. *Scand J Gastroenterol* **33**: 55-62, 1998.

- GREGERSEN H, EHRLEIN H: Motility studies in laboratory animals. In *Essentials of Experimental Surgery: Gastroenterology* **17**: 1-40, 1993.
- GREGERSEN H, ORVAR K, CHRISTENSEN J: Biomechanical properties of duodenal wall and duodenal tone during phase I and phase II of the MMC. *Am J Physiol* **263**: G795-G801, 1992.
- GRYBACK P, JACOBSSON H, BLOMQUIST L, SCHNELL PO, HELLSTROM PM: Scintigraphy of the small intestine: a simplified standard for study of transit with reference to normal values. *Eur J Nucl Med* **29**: 39-45, 2002.
- GSCHOSSMANN JM, BUENGER L, ADAM B, LIEBREGTS T, SALLER B, MANN K, GERKEN G, HOLTSMANN G: Diurnal variation of abdominal motor responses to colorectal distension and plasma cortisol levels in rats. *Neurogastroenterol Motil* **13**: 585-589, 2001.
- HASLER LH: Motility of the small intestine. In: *Textbook of Gastroenterology*. YAMADA T (ed), Philadelphia, JB Lippincott, 1995, pp 181-225.
- HUSEBYE E: The patterns of small bowel motility: physiology and implications in organic disease and functional disorders. *Neurogastroenterol Motil* **11**: 141-161, 1999.
- HUSEBYE E, SKAR V, HOVERSTAD T, IVERSEN T, MELBY K: Abnormal intestinal motor patterns explain enteric colonization with gram-negative bacilli in late radiation enteropathy. *Gastroenterology* **109**: 1078-1089, 1995.
- JOSEPHS MD, CHENG G, KSONTINI R, MOLDAWER LL, HOCKING MP: Products of cyclooxygenase-2 catalysis regulate postoperative bowel motility. *J Surg Res* **86**: 50-54, 1999.
- KATSCHINSKI M, STEINICKE C, REINSHAGEN M, DAHMEN G, BEGLINGER C, ARNOLD R, ADLER G: Gastrointestinal motor and secretory responses to cholinergic stimulation in humans. Differential modulation by muscarinic and cholecystokinin receptor blockade. *Eur J Clin Invest* **25**: 113-122, 1995.
- KELLOW JE, DELVAUX M, AZPIROZ F, CAMILLERI M, QUIGLEY EM, THOMPSON DG: Principles of applied neurogastroenterology: physiology/motility-sensation. *Gut* **45** (Suppl 2): II17-II24, 1999.
- KREIS ME, KASPAREK M, VOGT A, BECKER HD, ZITTEL TT, JEHLE EC: Postoperative colonic motility is increased and oral food intake facilitated following treatment with 5-HT receptor antagonist tropisetron in patient after colo-rectal surgery. *Gastroenterology* **120**: A473, 2001.
- KUEMMERLE JF: Motility disorders of the small intestine: new insights into old problems. *J Clin Gastroenterol* **31**: 276-281, 2000.
- KUIKEN SD, TYTGAT GNJ, BOECKXSTAENS GE: Role of endogenous nitric oxide in regulating antropyloroduodenal motility in humans. *Am J Gastroenterol* **97**: 1661-1667, 2002.
- LAMMERS WJ, DHANASEKARAN S, SLACK JR, STEPHEN B: Two-dimensional high-resolution motility mapping in the isolated feline duodenum: methodology and initial results. *Neurogastroenterol Motil* **13**: 309-323, 2001.
- LORDAL M, NAVALESI G, THEODORSSON E, MAGGI CA, HELLSTROM PM: A novel tachykinin NK₂ receptor antagonist prevents motility-stimulating effects of neurokinin A in small intestine. *Br J Pharmacol* **134**: 215-223, 2001.
- MADSEN JL, BRINCH K, HANSEN EF, FUGLSANG S: Gastrointestinal motor function in patients with portal hypertension. *Scand J Gastroenterol* **35**: 490-493, 2000.
- MANES G, MALFERTHEINER P: Relationship of Helicobacter pylori infection with gastrointestinal motility. *Ital J Gastroenterol Hepatol* **31**: 705-712, 1999.
- MARCIANI L, GOWLAND PA, SPILLER RC, MANOJ P, MOORE RJ, YOUNG RJ, YOUNG P, FILLERY-TRAVIS AJ: Effect of meal viscosity and nutrients on satiety, intragastric dilution, and emptying assessed by MRI. *Am J Physiol* **280**: G1227-G1233, 2001.
- MARIE I, LEVESQUE H, DUCROTTE P, DENIS P, BENICHOU J, HELLOT MF, CAILLEUX N, LE LOET X, JOLY P, LAURET P, COURTOIS H: Manometry of the upper intestinal tract in patients with systemic sclerosis: a prospective study. *Arthritis Rheum* **41**: 1874-1883, 1998.
- MARTIN MJ, STEELE SR, NOEL JM, WEICHMANN D, AZAROW KS: Total colonic manometry as a guide for surgical management of functional colonic obstruction: preliminary results. *J Pediatr Surg* **36**: 1757-1763, 2001.

- MATHISON R, LO P, TAN D, SCOTT B, DAVISON JS: The tripeptide feG reduces endotoxin-provoked perturbation of intestinal motility and inflammation. *Neurogastroenterol Motil* **13**: 599-603, 2001.
- MEDHUS AW, LOFTHUS CM, BREDESEN J, HUSEBYE E: Gastric emptying: the validity of the paracetamol absorption test adjusted for individual pharmacokinetics. *Neurogastroenterol Motil* **13**: 179-185, 2001.
- MELLANDER A: *Integration Between Interdigestive Motility and Epithelial Transport in the Proximal Small Intestine in Humans*. Doctoral Thesis. Gotenborg, Sweden, 1996.
- MELLANDER A, JARBUR K, SJOVALL H: Pressure and frequency dependent linkage between motility and epithelial secretion in human proximal small intestine. *Gut* **46**: 376-384, 2000.
- MIEDEMA BW, SCHWAB J, BURGESS SV, SIMMONS JW, METZLER MH: Jejunal manometry predicts tube feeding intolerance in the postoperative period. *Dig Dis Sci* **46**: 2250-2255, 2001.
- MOORE FA, COCANOUR CS, MCKINLEY BA, KOZAR RA, DESOIGNIE RC, VON MASZEWSKI ME, WEISBRODT NW: Migrating motility complexes persist after severe traumatic shock in patients who tolerate enteral nutrition. *J Trauma* **51**: 1075-1082, 2001.
- NEHRA V, CAMILLERI M, BURTON D, OENNING L, KELLY DG: An open trial of octreotide long-acting release in the management of short bowel syndrome. *Am J Gastroenterol* **96**: 1494-1498, 2001.
- OUYANG A: Chest pain of esophageal origin. *Hepatogastroenterology* **36**: 533-537, 1989.
- PALLOTTA N, BACCINI F, CORAZZIARI E: Ultrasonography of the small bowel after oral administration of anechoic contrast solution. *Lancet* **353**: 985-986, 1999.
- PENAGINI R, SPILLER RC, MISIEWICZ JJ, FROST PG, SILK DB: Effect of cholecystectomy on mouth-to-cecum transit of a liquid meal. *Dig Dis Sci* **33**: 19-22, 1988.
- PENNING C, GIELKENS HA, HEMELAAR M, LAMERS CB, MASCLEE AA: Reproducibility of antroduodenal motility during prolonged ambulatory recording. *Neurogastroenterol Motil* **13**: 133-141, 2001.
- PICARD C, WYSOCKI J, FIORAMONTI J, GRIFFITHS NM: Intestinal and colonic motor alterations associated with irradiation-induced diarrhoea in rats. *Neurogastroenterol Motil* **13**: 19-26, 2001.
- QUIGLEY EM. Gastric and small intestinal motility in health and disease. *Gastroenterol Clin North Am* **25**: 113-145, 1996.
- QUIGLEY EM: Disturbances in small bowel motility. *Baillieres Best Pract Res Clin Gastroenterol* **13**: 385-395, 1999a.
- QUIGLEY EM: Chronic intestinal pseudo-obstruction. *Curr Treat Options Gastroenterol* **2**: 239-250, 1999b.
- QUIGLEY EM, DEPREZ PH, HELLSTROM P, HUSEBYE E, SOFFER EE, STANGHELLINI V, SUMMERS RW, WILMER A, WINGATE A: Ambulatory intestinal manometry: a consensus report on its clinical role. *Dig Dis Sci* **42**: 2395-2400, 1997.
- QVIST N: Motor activity of the gallbladder and gastrointestinal tract as determinants of enterohepatic circulation. A scintigraphic and manometric study. *Dan Med Bull* **42**: 426-440, 1995.
- QVIST N, OSTER-JORGENSEN E, PEDERSEN SA, RASMUSSEN L, HOVENDAL C, HOLST JJ: Increases in plasma motilin follow each episode of gallbladder emptying during the interdigestive period, and changes in serum bile acid concentration correlate to plasma motilin. *Scand J Gastroenterol* **30**: 122-127, 1995.
- REMYNGTON M, MALAGELADA JR, ZINSMEISTER A, FLEMING CR: Abnormalities in gastrointestinal motor activity in patients with short bowels: effect of a synthetic opiate. *Gastroenterology* **85**: 629-636, 1983.
- SAMSOM M, BRINKMANN BH, LIGHVANI SS, BOURAS EP, DANIEL DA, O'CONNOR MK, CAMILLERI M: Gastric accommodation measured noninvasively in post-fundoplication and non-ulcer dyspepsia patients. *Gastroenterology* **118**: A389, 2000.
- SARNA SK, BRIEJER MR, SCHUURKES JA. 5-HT₃/5-HT₄ receptors in motility disorders. In: *Drug Development: Molecular Targets for GI Diseases*. GAGINELLA TS, GUGLIETTA A (eds), Totowa (NJ), New York, Humana Press, 2000, pp 177-203.
- SCHOONJANS R, VAN VLEM B, VAN HEDDEGHEM A, VANDAMME W, VANHOLOER R, LAMIERE A, LEFEBVRE R, DE VOS M: The ¹³C-octanoid breath test: validation of a new noninvasive method of measuring gastric emptying in rats. *Neurogastroenterol Motil* **14**: 287-293, 2002.
- SCHMIDT PT, BOZKURT A, HELLSTROM PM: Tachykinin-stimulated small bowel myoelectric pattern: sensitization by NO inhibition, reversal by neurokinin receptor blockade. *Regul Pept* **105**: 15-21, 2002.

- SCHMIDT T, PFEIFFER A, HACKELSBERGER N, WIDMER R, PEHL C, KAESS H: Dysmotility of the small intestine in achalasia. *Neurogastroenterol Motil* **11**: 11-17, 1999.
- SCHWARTZ MP, SAMSOM M, SMOUT AJ: Manometric artefacts suggesting compression of the duodenum by the superior mesenteric artery in healthy humans. *Neurogastroenterol Motil* **13**: 143-149, 2001.
- SEIDEL SA, HEGDE SS, BRADSHAW LA, LADIPO JK, RICHARDS WO: Intestinal tachyarrhythmias during small bowel ischemia. *Am J Physiol* **277**: G993-G999, 1999.
- SMALL PK, LOUDON MA, HAU CM, NOOR N, CAMPBELL FC: Large-scale ambulatory study of postprandial jejunal motility in irritable bowel syndrome. *Scand J Gastroenterol* **32**: 39-47, 1997.
- SMOUT AJ: Manometry of the gastrointestinal tract: toy or tool? *Scand J Gastroenterol Suppl*: 22-28, 2001.
- SOFFER E, THONGSAWAT S: Clinical value of duodenojejunal manometry. Its usefulness in diagnosis and management of patients with gastrointestinal symptoms. *Dig Dis Sci* **41**: 859-863, 1996.
- SPECHLER S J, CASTELL DO: Classification of oesophageal motility abnormalities. *Gut* **49**: 145-151, 2001.
- SPENCER NJ: Control of migrating motor activity in the colon. *Curr Opin Pharmacol* **1**: 604-610, 2001.
- STANGHELLINI V, CORINALDESI R: Stomach and duodenum. In: *An Illustrated Guide to Gastrointestinal Motility* KUMAR D, GUSTAVSSON S (eds). New York, John Wiley, 1988, pp 335-353.
- STANGHELLINI V, CORINALDESI R, TOSETTI C: Relevance of gastrointestinal motor disturbances in functional dyspepsia. *Baillieres Clin Gastroenterol* **12**: 533-544, 1998.
- STANGHELLINI V, COGLIANDRO R, COGLIANDRO L, DE GIORGIO R, BARBARA G, SALVIOLI B, CORINALDESI R: Clinical use of manometry for the diagnosis of intestinal motor abnormalities. *Dig Liver Dis* **32**: 532-541, 2000.
- SZURSZEWski JH: A migrating electric complex of canine small intestine. *Am J Physiol* **217**: 1757-1763, 1969.
- THOMSON AB, KEELAN M, THIESEN A, CLANDININ MT, ROPELESKI M, WILD GE: Small bowel review: normal physiology part 2. *Dig Dis Sci* **46**: 2588-2607, 2001.
- TOHARA K, UCHIDA Y, SUZUKI H, ITOH Z: Initiation of phase III contractions in the jejunum by atropine, hexamethonium and xylocaine in conscious dogs. *Neurogastroenterol Motil* **12**: 11-21, 2000.
- TORRENTS D, TORRES R, DE MORA F, VERGARA P: In vivo treatment with anti-nerve growth factor (NGF) prevents exacerbated motor responses in the intestines of *T. spiralis* infected rats. *Gastroenterology* **120**: A71, 2001.
- TOULOUSE M, FIORAMONTI J, MAGGI C, UENO L: Role of NK₂ receptors in gastric barosensitivity and in experimental ileus in rats. *Neurogastroenterol Motil* **13**: 45-53, 2001.
- WIDMER R, SCHMIDT T, PFEIFFER A, KAESS H: Computerized analysis of ambulatory long-term small-bowel manometry. *Scand J Gastroenterol* **29**: 1076-1082, 1994.
- ZITTEL TT, HUGE A, KREIS ME, BECKER HD, JEHLE EC: Tegaserod (HTF 919), a new 5-HT₄ receptor agonist, increases postoperative gastric and small intestinal motility in rats. In: *Falk symposium 112. Neurogastroenterology. From the Basic to the Clinics*. KRAMMER H, SINGER MV (eds), Dordrecht, Kluwer Academic Publishers, 2000, pp 214-221.

Reprint requests

Mark Berner Hansen, Chief Surgeon, DMSc., Department of Surgical Gastroenterology K, Bispebjerg University Hospital of Copenhagen, Bispebjerg Bakke 23, 2400 Copenhagen NV, Denmark. E-mail: mbh@dadlnet.dk