

Reverse Endoventricular Artificial Obturator in Tricuspid Valve Position. Experimental Feasibility Research Study

J. SOCHMAN¹, J. H. PEREGRIN², D. PAVCNIK³, B. T. UCHIDA³, H. A. TIMMERMANS³, D. SEDMERA^{4,5}, O. BENADA^{6,7}, O. KOFRONOVA⁶, F. S. KELLER³, J. ROSCH³

¹Clinic of Cardiology, Institute for Clinical and Experimental Medicine, Prague, Czech Republic,

²Department of Diagnostic and Interventional Radiology, Institute for Clinical and Experimental

Medicine, Prague, Czech Republic, ³Dotter Interventional Institute, Oregon Health Science

University, Portland, OR, USA, ⁴Department of Cardiovascular Morphogenesis, Institute of

Physiology Academy of Sciences of the Czech Republic, Prague, Czech Republic, ⁵Institute of

Anatomy, First Faculty of Medicine, Charles University in Prague, Prague, Czech Republic,

⁶Institute for Microbiology, Academy of Sciences of the Czech Republic, Prague, Czech Republic,

⁷Department of Biology, J. E. Purkinje University, Ústí nad Labem, Czech Republic

Received May 29, 2013

Accepted August 28, 2013

On-line January 8, 2014

Summary

The concept of vena contracta space reduction in tricuspid valve position was tested in an animal model. Feasibility of specific artificial obturator body (REMOT) fixed to the right ventricular apex and interacting with tricuspid valve leaflets was evaluated in three different animal studies. Catheter-based technique was used in three series of experiment in 7 sheep. First acute study was designed for evaluation if the screwing mode of guide wire anchoring to the right ventricular apex is feasible for the whole REMOT body fixing. Longer study was aimed to evaluate stability of the REMOT body in desired position when fixing the screwing wire on its both ends (to the right ventricular apex and to the skin in the neck area). X-ray methods and various morphological methods were used. The third acute study was intended to the REMOT body deployment without any fixing wire. In all of 7 sheep the REMOT was successfully inserted into the right heart cavities and then fixed to the right ventricular apex area. When the REMOT was left *in situ* more than 6 months it was stable, induced adhesion to the tricuspid valve leaflet and was associated with a specific cell invasion. Releasing of the REMOT from the guiding tools was also successfully verified. Deployment of the obturator body in the aim to reduce the tricuspid valve orifice is feasible and well tolerated in the short and longer term animal model. Specific cell colonization including neovascularization of the obturator body was observed.

Key words

Tricuspid valve regurgitation • Catheterization • Myxoma-like principle • Tricuspid annular plane systolic excursion (TAPSE)

Corresponding author

J. Sochman, Clinic of Cardiology, Institute for Clinical and Experimental Medicine, Videnska 1958/9, 140 21 Prague 4 – Krc, Czech Republic. Fax: +420 26136 2986. E-mail: jaso@medicon.cz

Introduction

At present, recalcitrant atrioventricular regurgitation that can no longer be controlled pharmacologically, can be managed surgically or using catheter-based approaches. Attention was more focused on the mitral valve, however the principles of valve correction are similar for the tricuspid valve. Options in mitral valve repair derived from past include surgical replacement, annular reduction and, finally, valvuloplasty to improve leaflet and chordal function. Several ongoing studies explore the potential of various transcatheter techniques to treat annular enlargement. Another possibility is to fuse both valve leaflets using a catheter-based procedure.

While, to date, the tricuspid valve has received less attention than deserved, an estimated 0.8 % of the

general population in the USA has a detectable tricuspid valve malfunction (Singh *et al.* 1999, Stuge *et al.* 2006, Chan *et al.* 2009). There is also estimated some 4,000-8,000 patients with a tricuspid valve defect – that most often results in regurgitation – who undergo surgery in the USA each year (Freed *et al.* 1999, Singh *et al.* 1999, Gammie *et al.* 2007). Many surgeons tend to ignore the tricuspid valve during left-heart valve procedures in the hope its function will improve once the pressure-volume ratio has normalized spontaneously. Among the catheter-based techniques, the optimal strategy is orthotopic implantation of the whole prosthetic valve. However, this approach is faced with various technical problems in terms of firm anchoring of the valve, risk for embolism, and induction of a variety of arrhythmias. As a result, while this approach is beyond our capabilities using transcatheter techniques at the moment, heterotopic valve replacement is a realistic consideration (Lauten *et al.* 2010, 2011). Annuloplasty in this position seems to be out of question; however, transcatheter leaflet suturing is feasible. Suturing the leaflets together with their subsequently induced fusion will eventually split the valve orifice into several smaller sectors: this has been documented using the original surgical (triple-orifice) technique (Uzdavinyis *et al.* 2000, De Bonis *et al.* 2004). In patients with co-existing annular dilatation and valve leaflet lesion, repair is at the limit of feasibility. Experimentally, tricuspid regurgitation can be managed by the simultaneous placement of two valves at a site where both caval veins enter the right ventricle, i.e., the twin valve caval stent (TVCS) (Sochman *et al.* 2011). Perhaps the last theoretical possibility is reduction of the space between the valve leaflets (coaptation gaping zone). Essentially, this approach can be best described as a reverse myxoma: a myxoma is typically fixed in the inter-atrial septum with a substantial negative impact on ventricular filling in diastole. In our concept, a “reverse myxoma” would be fixed in the ventricular apex diminishing the space between valvular leaflets during tricuspid annular plane systolic excursions (TAPSE) without any restrictions in diastole. Yet another possible and desirable strategy would be fusion of this quasi-myxoma with valvular leaflet(s). A similar approach proposed for mitral regurgitation repair is associated with the name of T. C. Piemonte (CardiosolutionsTM, Percu-ProTM system or MitraSpacer) and referred to as the spacer (<http://www.cardiosolutionsinc.com/future-products.html>). However, we have failed to identify any paper, experimental or clinical, in the relevant literature,

addressing this issue.

The text below reviews the potential of using the above palliative, transcatheter approach in the tricuspid setting.

Material and Methods

Principle of action

Tricuspid annular plane systolic movement (TAPSE) is the force driving any foreign body deployed artificially into the area between the right ventricular apex and tricuspid valve leaflets when fixed to the internal apex. Reduction of interleaflet area is a logical result of this measure. Another option is based on induced fusion of the body and valve leaflet(s) (Fig. 1).

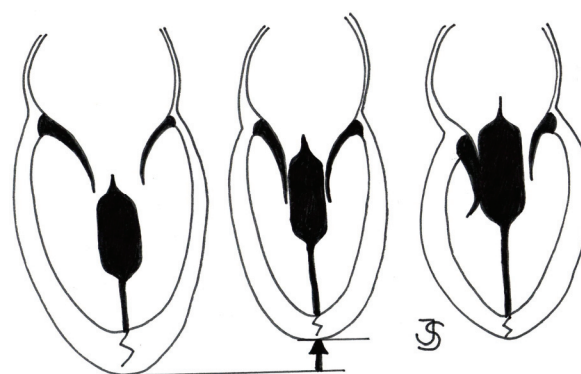


Fig. 1. Principles of the REMOT device action. **Left:** diastole (free flow from the right atrium), **middle:** systole (blocking of regurgitant area caused by TAPSE-mediated movement of the REMOT), **right:** leaflet-REMOT device fusion.

The body created for the purpose of annular area decrease is referred to as the Reverse Endoventricular Myxoma-like artificial Obturator in Tricuspid valve regurgitation (REMOT). Unlike our previous study with the TVCS (10), this pilot procedure did not involve papillary muscle avulsion. It goes without saying that placement of a foreign body into the tricuspid valve orifice deforms the coaptation zone (vena contracta). The obturator was fixed in the right ventricular apex with a screw being an integral part of the obturator stalk (for the short-term as well as long-term experiments).

Animals

Animal experiments were carried out in 7 adult sheep weighing 45-55 kg. Experiments were conducted at the Experimental Research Laboratory of the Institute of Clinical and Experimental Medicine in Prague, Czech Republic and the Dotter Interventional Institute Research

Laboratory, Oregon Health & Science University, Portland, Oregon, USA. All experiments were conducted according to standard practices for handling laboratory animals (Guide for the Care and Use of Laboratory Animals, U. S. National Institutes of Health (NIH) Publication No. 85-32, rev. 1996) and simultaneously approved by the Institutional Animal Care and Use Committees of both institutions.

REMOT design

The REMOT device was manufactured by ELLA-CS, Hradec Kralove, Czech Republic according to our own calculations, design and instructions. The device was based on the ELLA-designed SX stent described in detail previously (Sochman *et al.* 2006, 2010). In our experiments, the stent was salami-shaped; at each end, it was buried conically in a tube with an inner diameter of 1.0 mm. The whole obturator was 30 mm long with another 7 mm cone-shaped part at either end. Its outer diameter was 15-17 mm. A nitinol 0.16-mm wire was used. The whole device was coated with elastic Spandex fabric, elasticity 20 %, 220 g/m² (Wan Feng Knit Garment Co., Suzhou, China). The coating was fixed to the wire skeleton with sutures (Fig. 2, left panel).

The REMOT was intended for use both in short-term and long-term experiments. For short-term deployment, the device was advanced using a guiding sheath technique into the right ventricular cavity and fitted with a thread to fix it in the area of right ventricular apex (Fig. 2, right panel). Next, distance tubes whose length was based on the individually measured distance between the apex and the tricuspid valve annular plane were placed between the end of the thread and the distal end of the REMOT device.

For long-term experiments, a flexible metallic spiral, again fitted with a fixation thread, was attached to the distal segment of the REMOT device. The length of the “pedicle” was again selected depending on the distances measured. Fixation thread was – in this particular case – an integral functional part of long fixation wire with appropriate torsion properties allowing screwing mechanism.

Experimental design

Three series of experiments were conducted. First acute study was intended for evaluation if the screwing mode of guide wire anchoring into the right ventricular apex is feasible for the whole REMOT body anchoring. Then longer study was aimed to evaluate the long-term

REMOT stability in its desired position using guide wire fixed on its both ends: one end in the right ventricular apex and the other one to the skin. Moreover, the interaction of REMOT with the right heart structures interaction was planned to study. This interaction includes evaluation of adhesion of the REMOT cover to neighbouring structures and cell reactions as well. The third and final part of the study was aimed to acute evaluation of the REMOT detaching without any fixing wire.

First series

In the first series, three animals were used to test exclusively the possibility of screwing the guidewire into the right ventricular apex and coaxial placement of the REMOT device in the right ventricular region, about a proximal third above the tricuspid valve plane. The experiment took about 3 hours to complete and was conducted under angiographic guidance combined with continuous EKG and oxygen saturation monitoring. In this experiment, the fixation wire was thus projecting from the vascular access.

Second series

In this series, the experiments (2 sheep) took several months to complete. The fixation wire was cut shorter and fitted with an atraumatic end and an eye fixed in subcutaneous tissue by the suture. The wound was closed with layered suture. Given the sheep strong flocking behavior, the animal lived moving freely about the shed in the company of other animals. This long lasting part of experiment was monitored by a veterinarian.

Third series

This series was designed to mimic the possibility of anchoring the REMOT device, without the use of a fixation wire but using only the thread in the lower part of the device, in the right ventricular apex as done with screwable permanent pacing leads. Releasing of the tools (guide wire or sheath) used to deploy the REMOT was the goal. Two additional sheep were used for this purposes and the experiments took also 3-4 hours to complete as in the first series.

Technique of REMOT device insertion

A 16F sheath was advanced *via* access into the right jugular vein, followed by right ventriculography and right atrial contrast imaging in several planes. A marking pigtail catheter was employed to measure the distances between the apex and the annular plane. The right

ventricular size was also determined. These measures were common for all three series of the experiment. In short-term experiments (first series), the REMOT was screwed into the right ventricular apex using a guiding sheath and a pin wise. Using the front-loading technique, the REMOT device was inserted into a 14F sheath and advanced further into the right ventricular cavity with a pusher and further secured by 4-6 turns. Continuous i.v. heparin infusion was used during the procedure to prevent thrombosis.

In the long-term experiments (second series), the REMOT was advanced coaxially using a long stiff wire with a similar thread end. Appropriate distance derived from previous measurement was adjusted between apex and tricuspid annular plane using metal tubing. The REMOT device was then deployed and further secured with an *in situ* lock made from a pre-deformed S-shaped steel tube. The opposite end of the wire served as the second lock: desired position of the sheep neck to wire length was determined. The eye lock end was created on this part of the wire and attached using deformation force of small pincers. Then the excess length of the wire was cut off and the eye lock was sutured and the access cut down area was closed using multilayer stitches. Immediately before the experiment the sheep was given i.v. ceftriaxone (Ceftriaxon, Kabi Fresenius, Prague, Czech Republic) at a dose of 1.0 g; the same dose was administered repeatedly once a day over the next four days. During the course of the experiment, the sheep was infused at least 5,000 U of heparin intravenously, to be followed by the low-molecular weight heparin enoxaparin (Clexane, Sanofi, Aventis, Bratislava, Slovak Republic) at a dose of 0.3 ml subcutaneously over the next 10 days and then no anticoagulation agent was administered. In addition, i.v. omeprazol (Helicid, Zentiva, Prague, Czech Republic) was administered at a dose of 40 mg once daily for the next four days as a prevention of gastric ulceration risk.

In the final short-term experiments leaving the REMOT device *in situ* without a fixation wire (third series), the proximal end of the device was fitted with a detachable lock in the form of a latch or a thread running opposite to the fixation thread. Connection to the handling part of the deployment device allowed torque transmission to the end of the fixation spiral of the REMOT device. Upon screwing the REMOT device into the right ventricle, the handling part was disengaged and removed.

No hemodynamic study was performed at this stage of experiment even though coaptation of the tricuspid

valve leaflets was apparently distorted by REMOT presence. This stage of experiment was pointed at stability of the REMOT body and associated cell reactions.

Morphological examination

The REMOT was carefully dissected free from the heart, to which it was attached by the guide wire (embedded in the right ventricular wall) and a fine sheet of fibrous tissue containing blood vessels. It was then sliced in half to examine the inner structure and cut into pieces, which were processed for light and electron microscopic examination. For electron microscopy, the samples were fixed in glutaraldehyde overnight at 4 °C, rinsed in cacodylate buffer, and stored at 4 °C. For transmission electron microscopy, small pieces of tissue ($\pm 1 \times 1$ mm) were separated from the wire and cover of the device, postfixated in osmium tetroxide, dehydrated, and embedded into epoxy resin. Semithin sections were cut using a glass knife. After selecting the regions of interest, ultrathin sections were cut and stained with uranyl acetate and Reynolds solution for examination on a Philips CM100I transmission electron microscope (FEI). Panoramic high-resolution images were captured using a slow scan Mega View II camera and automatically assembled using the MIA module (Analysis 3.2), as described (Benes *et al.* 2011). For scanning electron microscopy, fixed samples were thoroughly washed with cacodylate buffer, pH 7.2, dehydrated through alcohol series (25, 50, 75, 90, 96 and 100 %), transferred into absolute acetone and dried using Balzers 010 critical point dryer. Dried samples were sputter-coated with gold and examined in Aquasem scanning electron microscope (Tescan, Czech Republic) at 15 kV in secondary electron mode. Digitally recorded images were processed using AnalySIS 3.2 software suite (Olympus, formerly SiS GmbH, Germany).

Samples for histology were fixed in buffered 4 % paraformaldehyde overnight at 4 °C, rinsed in phosphate buffered saline, and processed into paraffin for embedding *via* ethanol gradient series. Serial sections were cut at 10 μ m on a rotary microtome (Leica), mounted on silane-coated Superfrost slides, and stained with Alcian Blue/Hematoxylin-Eosin (general staining), picrosirius red (collagen), and cell type specific antibodies: anti-smooth muscle actin (Sigma #A 2574) for smooth muscle and myofibroblasts, anti-vWF (Sigma #3520, endothelial cells), and anti-collagen (MD Biosciences #203002, extracellular matrix). Cell nuclei were counterstained with Hoechst dye and the samples were imaged on




Fig. 2. The REMOT device. **Left panel:** 1 – thread anchor, 2 – Spandex cover (wire skeleton inside can be clearly seen), 3 – guide wire. **Right panel** shows the device during sampling for histology. The wire traverses the tricuspid orifice, and the thread at the tip is fixed to the right ventricular (RV) apex (arrowhead). The sheet containing the blood vessels connecting the device to the endocardium is indicated by the arrow. The surface is as shiny as the endocardium with no thrombus.

a Leica SPE confocal microscope.

For evaluation of the presence of adipocytes, frozen sections were prepared after transferring the first tissue to the OCT media using sacharose gradient, and stained with Sudan Black or Oil Red using standard protocols.

Results

In all animals in the first series, we were successful in placing the REMOT device into the desired position. The fixation wire was easily screwed into the right ventricular apex: as a result the lower 2/3 of REMOT body were retained in the right ventricular cavity while the upper part of the REMOT device passed through the tricuspid orifice into the lower part of the right atrium. No arrhythmias were noted during the monitoring period. No change in the position of the REMOT device after 3 hours after fixation wire exteriorization was observed. Upon completion of the experiment, when testing anchoring of the fixation wire, with the use of force, considerable resistance was felt with a corresponding movement of the whole heart as demonstrated by x-ray. However, the wire did not get torn off the heart.

On autopsy, there was one case of the wire thread entering the pericardial cavity; without any sign of pericardial blood collection.

Second series

The first animal was sacrificed after 103 days. The REMOT device was present in its original position. When extracted, the surface of the REMOT device was not fused with surrounding tissue, but was covered with a neoendothelium and subendothelial fibrous tissue. More

detailed study using various histology techniques is described in the second sheep of this series, however the results are similar.

The second animal had the REMOT device *in situ* for a total of 197 days (the end of the guidewire was fitted with an eye and sutured into subcutaneous tissue in the region of the access site in the neck). The REMOT device did not get dislodged and no veterinary problems were noted over the more than six months of the sheep's life with REMOT. On autopsy, the REMOT device was covered with a shiny, smooth, pale pink membrane partly adhering to the right ventricular wall under a tricuspid valve leaflet (Fig. 2). On palpation, the REMOT was semirigid, but flexible, showing a jelly mass on cross section.

The entire lumen of the device was filled by whitish, elastic tissue (Fig. 3). Scanning electron microscopy showed that the substance was rich in extracellular matrix, arranged in bundles of woven structure. Histological staining revealed that the structure was also cellular, with blood supply consisting of capillaries as well as small caliber arteries with typical three-layered wall architecture. Smooth muscle staining revealed that numerous cells were positive, marking them together with their morphology as myofibroblasts. The extracellular matrix contained a large amount of collagen, which was arranged in fibrils but lacked the orderly organization into orderly higher-order bundles typical of tendons or mature tissue detectable by picrosirius red staining (data not shown). Some cell also showed lipid droplets in her cytoplasm (Fig. 3).

No microbial colonization was observed. No adverse events or health problems were reported by veterinary inspector.

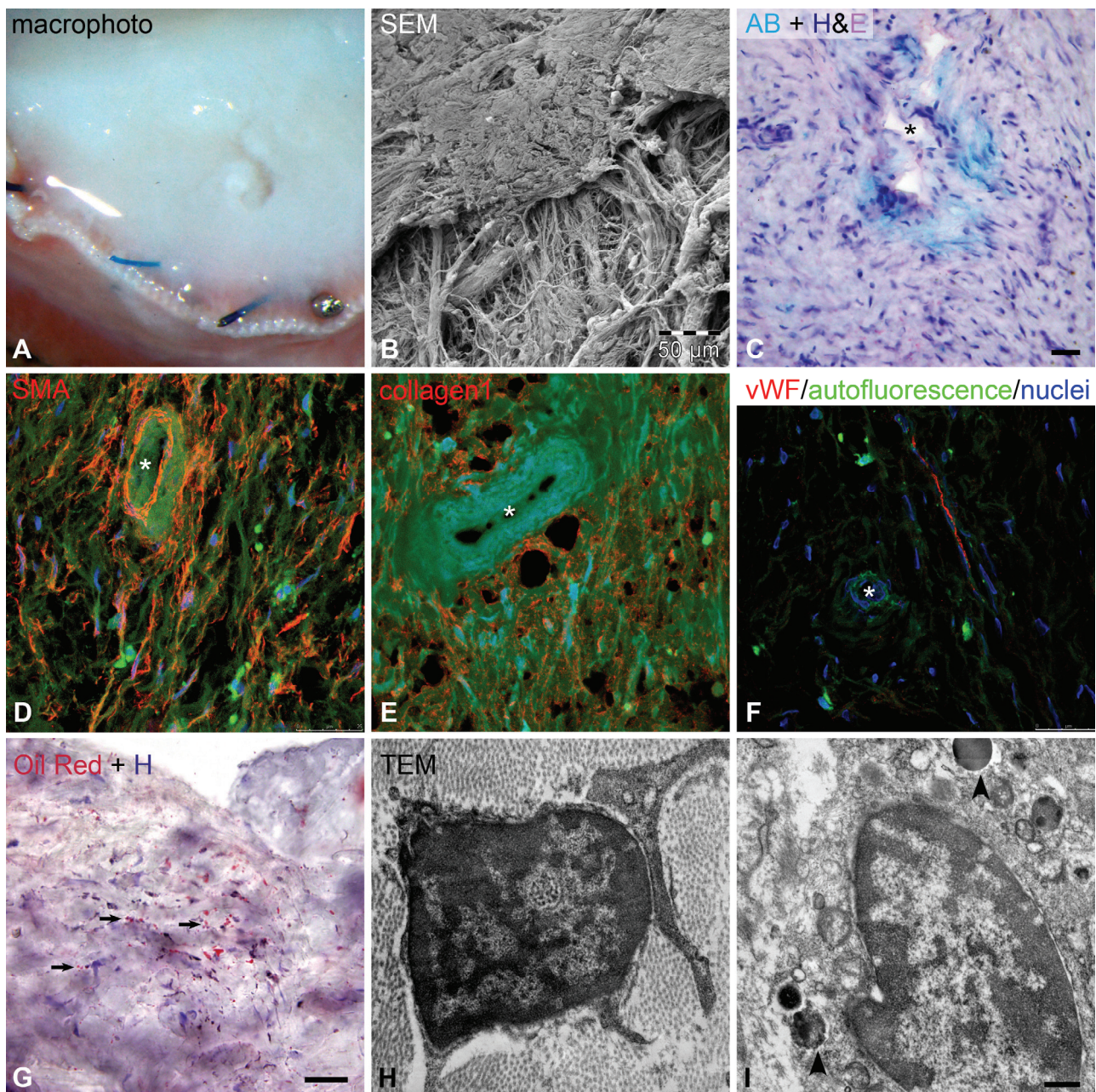


Fig. 3. Histology: REMOT 197 days in the right heart (second series). **A)** A macrophotograph taken shortly after fixation showing the uniform, whitish elastic tissue filling the inside of the REMOT. The skeleton of the device containing nylon fibers and wires is also visible on cross section. **B)** Scanning electron microscopy showing the mixture of cells and extracellular matrix. **C)** Alcian Blue/H&E staining showing a small artery (asterisk) with well-organized wall (stained blue). Scale bar 25 μ m. **D)** Anti-collagen staining showing positivity throughout the extracellular matrix. Cell nuclei are counterstained blue with the Hoechst dye (the same scale). **E)** Anti-smooth muscle actin staining shows the middle layer of the artery (asterisk) as well as numerous spindle-shaped myofibroblasts embedded in the extracellular matrix. Scale bars 25 microns as in previous panel. **F)** Anti-von Willebrand factor staining labeling the endothelial cells in a capillary. **G)** Oil Red staining lipid droplets (arrow) in the cytoplasm of adipocytes. Scale bar 254 μ m. **H)** Transmission electron micrograph showing the nucleus of a cell with thin layer of cytoplasm surrounded by numerous fibrils. Scale bar 100 nm. **I)** Dark lipid droplets confirming the observations from panel G. Scale bar 100 nm.

Third series

Once deployed into the apical region, the REMOT device was successfully disengaged. In one case, the device was not fixed right into the apex but somewhat laterally (Fig. 4).

Still, the REMOT device was anchored firmly

while not inducing tamponade.

Discussion

Artificial material not based on natural valve membranes such as small intestine submucosa (SIS) or

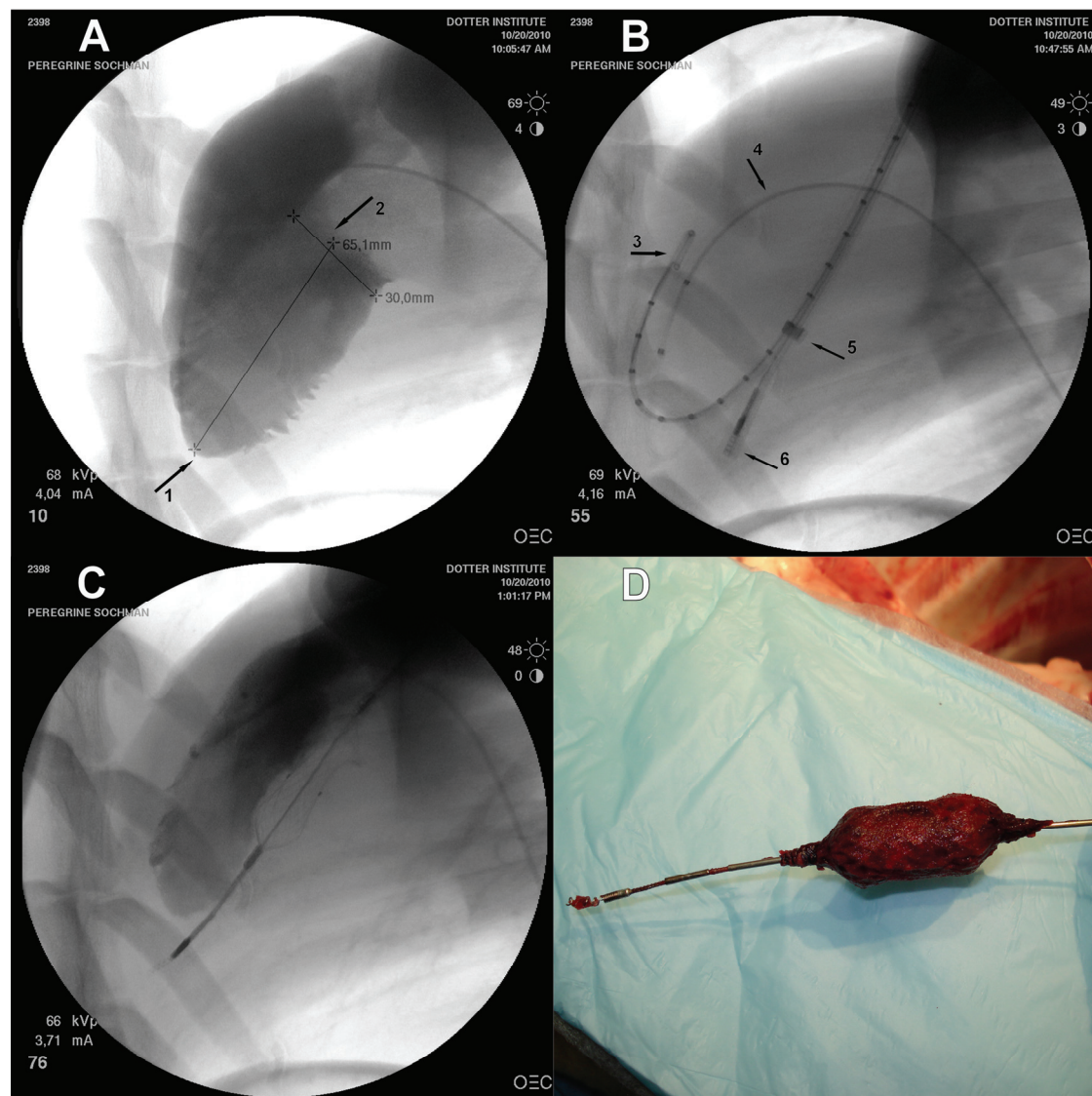


Fig. 4. Procedure of REMOT implantation in steps (third series). **A)** Right ventriculography measurement: 1 – true internal apex, 2 – tricuspid annular plane. **B)** REMOT advancing: 3 – marking pigtail catheter advanced *via* the jugular vein, 4 – regular pigtail advanced from the femoral vein, 5 – contrast marker end of advancing sheath, 6 – thread end of REMOT (partially out of the sheath). **C)** REMOT screwed in (not in the true internal apex in this particular case), contrast agent delineates the lateral part of REMOT, proximal end of REMOT is in the right atrium (above tricuspid annular plane). **D)** Extracted REMOT after 3 hours working *in situ*. Spandex cover was well impregnated by blood, thread end contained remnants of endomyocardium isolated by extraction tensile force during autopsy.

polymers undergoes substantial changes as early as after 3 months (Pavcnik *et al.* 2009). These changes are regarded as disadvantageous and degenerative due to native cell colonization and final membrane thickening. New inert membranes with resistant properties against cell invasion and interaction are presently unavailable. However, this “undesirable”, but stereotypical cell reaction in other experiments can serve as a substantial advantage in the current concept of the REMOT device. The construction and principle of reverse myxoma require estimation of the foreign body size, without having to go to extreme as may be the case in clinical practice (Shirani *et al.* 1993). Model experiments have

suggested the volume of the body placed in intraventricular position should not exceed 18 cm^3 (Liedtke *et al.* 1976). In theory, TAPSE as the driving force could move the REMOT device unless fixed with a string at either end. When measured in healthy individuals, TAPSE is about 20 mm while decreasing below 15 mm in those with ventricular systolic dysfunction (18-24) (Ohio *et al.* 2000, Forfia *et al.* 2006, Saxena *et al.* 2006, Lee *et al.* 2007, Tamborini *et al.* 2007, Lossnitzer *et al.* 2008, Lopez-Candales *et al.* 2009). The REMOT device can only be fixed at two poles: possibly using a stent in the superior vena cava or in the right ventricular apical region (alternatively in the

interventricular septum). However, if anchored in the superior vena cava, the TAPSE mechanism would be lost, which is why we opted for the endoventricular type of fixation.

Our study was designed to test whether a body with a volume not greater than 10 cm³ can be inserted *via* the right heart cavities and whether it is technically feasible to anchor it firmly. Further, we tested the technique of implantation using either the fixation wire left in the animal's body or the detachable technique. Finally, our long-term experiment was designed to analyze the REMOT device colonization with cells and tolerability.

It is evident that cellularity of the structure necessitated sufficient blood supply, which was derived from the endocardium and was brought by mature, small caliber arteries. This allowed differentiation of the cells into typical cell types of the connective tissue. The organization was fairly isotropic, with perhaps slightly higher cellularity close to the wall formed by the artificial structures (wires, cover membrane). In both animals of the second series, there was developed external blood supply of the structure.

To date, these pilot experiments have been conducted without inducing injury to the tricuspid valve papillary muscles. As stated above, we consider deformation of the tricuspid valve coaptation zone due to foreign body deployment in the tricuspid orifice non-

physiological.

Despite a rare mention of “spacer principle” no experimental verification of appropriate feasibility does exist (Chiam *et al.* 2011). Hemodynamic studies should be performed in a long-term experiments, and moreover with a papillary muscle avulsion. Permeable properties of a device cover membrane as well as pore sizes could be responsible for inner cell invasion and their final differentiation with corresponding neoangiogenesis induction for appropriate blood supply of such “viable artificial” body. Vice versa impermeable membrane could be neoendothelized only. These derived aspects of cell research should be also further studied.

Conflict of Interest

There is no conflict of interest.

Acknowledgements

This work was supported by Ministry of Health of the Czech Republic within the project for the development of research organization 00023001 (IKEM) – institutional support. The Center for Experimental Medicine (IKEM) received financial support from the European Commission within the Operational Program Prague-Competitiveness; project “CEVKOON” (#CZ.2.16/3.1.00/22126). Support outside IKEM involved Academy of Sciences Institutional Grants RVO: #6138897, and #67985823, and Charles University support PRVOUK-P35/LF1/5.

References

- BENES J, KAZDOVA L, DRAHOTA Z, HOUSTEK J, MEDRIKOVA D, KOPECKY J, KOVAROVA N, VRBACKY M, SEDMERA D, STRNAD H, KOLAR M, PETRAK J, BENADA O, SKAROUPKOVA P, CERVENKA, L, MELENOVSKY V: Effect of metformin therapy on cardiac function and survival in a volume-overload model of heart failure in rats. *Clin Sci* **121**: 29-41, 2011.
- CHAN KMJ, ZAKKAR M, AMIRAK E, PUNJABI PP: Tricuspid valve disease: pathophysiology and optimal management. *Progress Cardiovasc Dis* **51**: 482-486, 2009.
- CHIAM PTL, RUIZ CE: Percutaneous transcatheter mitral valve repair. A classification of the technology. *JACC Cardiovasc Interv* **4**: 1-13, 2011.
- DE BONIS M, LAPENA E, LA CANNA G, GRIMALDI A, MAISANO F, TORRACA F, CALDAROLA A, ALFIERI O: A novel technique for correction of severe tricuspid valve regurgitation due to complex lesions. *Eur J Cardiothoracic Surg* **25**: 760-765, 2004.
- FORFIA PR, FISHER MR, MATYSI SC, HOUSTEN-HARRIS T, HEMNES AR, BORLAUG BA, CHAMERA E, CORRETTI MC, CHAMPION HS, ABRAHAM TP, BORGIS RE, HASSOUN PM: Tricuspid annular displacement predicts survival in pulmonary hypertension. *Am J Respir Crit Care Med* **174**: 1034-1041, 2006.
- FREED LA, LEVY D, LEVINE RA, LARSON MG, EVANS JC, FULLER DL, LEHMAN B, BENJAMIN EJ: Prevalence and clinical outcome of mitral valve prolapse. *N Engl J Med* **341**: 1-7, 1999.

- GAMMIE JS, O'BRIEN SM, GRIFFITH BP, FERGUSON TB, PETERSON ED: Influence of hospital procedural volume on care process and mortality for patients undergoing elective surgery for mitral regurgitation. *Circulation* **115**: 881-887, 2007.
- <http://www.cardiosolutionsinc.com/future-products.html>
- LAUTEN A, FERRARI M, HEKMAT K, PFEIFER R, DANNBERG G, RAGOSCHKE-SCHUMM A, FIGULLA HA: Heterotopic transcatheter tricuspid valve implantation: first-in-man application of novel approach to tricuspid regurgitation. *Eur Heart J* **32**: 1207-1213, 2011.
- LAUTEN A, FIGULLA HR, WILlich C, LAUBE A, RADEMAKER W, SCHUBERT H, BISCHOFF S, FERRARI M: Percutaneous caval stent valve implantation: investigation of an interventional approach for treatment of tricuspid regurgitation. *Eur Heart J* **31**: 1274-1281, 2010.
- LEE CY, CHANG SM, HSIAO SH, TSENG JC, LIN SK, LIU CP: Right heart function and scleroderma: insights from tricuspid annular plane systolic excursion. *Echocardiography* **24**: 118-125, 2007.
- LIEDTKE AJ, HUGHES HC, ZELIS R: Functional reductions in left ventricular volume. Minimum chamber size consonant with effective hemodynamic performance. *J Thorac Cardiovasc Surg* **1**: 195-206, 1976.
- LOPEZ-CANDELES A, RAJAGOPALAN N, SAXENA N, GULYASY B, EDELMAN K, BAZAZ R: Right ventricular systolic function is not the sole determinant of tricuspid annular motion. *Am J Cardiol* **98**: 973-977, 2009.
- LOSSNITZER D, STEEN H, LEHRKE S, KOROSOGLOU G, MERTEN C, GIANNITSIS E, KATUS HA: MAPSE and TAPSE measured by MRI correlate with left and right ventricular ejection fraction and NTpro BNP in patients with dilated cardiomyopathy. *J Cardiovasc Magnetic Resonance* **10** (suppl A): A238, 2008.
- OHIO S, RECUSANI F, KLEERSY C, SEBASTIANI R, LAUDISA ML, CAMPANA C, GAVAZZI A, TAVAZZI L: Prognostic usefulness of the tricuspid annular plane systolic excursion in patients with congestive heart failure secondary to idiopathic or ischemic dilated cardiomyopathy. *Am J Cardiol* **85**: 837-842, 2000.
- PAVCNIK D, OBERMILLER J, UCHIDA BT, VAN ALSTINE W, EDWARDS JM, LANDRY GJ, KAUFMAN JA, KELLER FS, ROSCH J: Angiographic evaluation of carotid artery grafting with prefabricated small-diameter, small-intestinal submucosa grafts in sheep. *Cardiovasc Intervent Radiol* **32**: 106-113, 2009.
- SAXENA N, RAJAGOPALAN N, EDELMAN K, LOPEZ-CANDELES A: Tricuspid annular systolic velocity: a useful measurement in determining right ventricular systolic function regardless of pulmonary artery pressure. *Echocardiography* **23**: 750-755, 2006.
- SHIRANI J, ISNER JM, ROBERTS WC: Are autopsies still useful? Thanks goodness we didn't know. Not all tumors are bad tumors. Most of the cavity has to be filled before trouble occurs. *Am J Cardiol* **72**: 371-372, 1993.
- SINGH JP, EVANS JC, LEVY D: Prevalence and clinical determinants of mitral, tricuspid, and aortic regurgitation (the Framingham Study). *Am J Cardiol* **83**: 897-902, 1999.
- SOCHMAN J, PEREGRIN JH, PAVCNİK D, UCHIDA BT, TIMMERMANS HA, SHIMOHIRA M, CHOI YH, KELLER FS, ROSCH J: Twin valve caval stent for functional replacement of incompetent tricuspid valve: a feasibility animal study. *Cardiovasc Intervent Radiol* **34**: 174-179, 2011.
- SOCHMAN J, PEREGRIN JH, PULDA Z, PAVCNİK D, UCHIDA BT, TIMMERMANS HA, ROSCH J: A new cone-shaped aortic valve prosthesis for orthotopic position: an experimental study in swine. *Cardiovasc Intervent Radiol* **33**: 330-335, 2010.
- SOCHMAN J, PEREGRIN JH, ROCEK M, TIMMERMANS HA, PAVCNİK D, ROSCH J: Percutaneous transcatheter one-step mechanical aortic disc valve prosthesis implantation: a preliminary feasibility study in swine. *Cardiovasc Intervent Radiol* **29**: 114-119, 2006.
- STUGE, O, LIDDICOAT J: Emerging opportunities for cardiac surgeons with structural heart disease. *J Thorac Cardiovasc Surg* **132**: 1258-1261, 2006.
- TAMBORINI G, PEPI M, GALLI CA, MALTAGLIATI A, CELESTE F, MURATORI M, REZVANIEH S, VEGLIA F: Feasibility and accuracy of a routine echocardiographic assessment of right ventricular function. *Int J Cardiol* **115**: 86-89, 2007.
- UZDAVINYS G, VOLUCKIENE E, GREBELIS A, BORISAITE O: A new "Triple orifice repair" procedure for tricuspid insufficiency (initial experience). *Medicina* **36**: 1317-1323, 2000.