

---

REVIEW

---

## Thyroid Nodules: Pathophysiological Insight on Oncogenesis and Novel Diagnostic Techniques

J. KRÁTKÝ<sup>1</sup>, H. VÍTKOVÁ<sup>1</sup>, J. BARTÁKOVÁ<sup>1</sup>, Z. TELIČKA<sup>1</sup>, M. ANTOŠOVÁ<sup>1</sup>,  
Z. LÍMANOVÁ<sup>1</sup>, J. JISKRA<sup>1</sup>

<sup>1</sup>Third Department of Medicine, First Faculty of Medicine, Charles University, General University Hospital, Prague, Czech Republic

Received March 20, 2014

Accepted April 30, 2014

---

### Summary

Thyroid nodules are a very frequent pathology among common population. Despite the vast majority of them are of benign origin, the incidence of thyroid cancer is currently rather rising. Although there are several risk factors of thyroid cancer and several clinical, ultrasound, biochemical and molecular diagnostic markers, the exact mechanisms of thyroid oncogenesis and the linkage between thyroid nodule ultrasound appearance and its biological character remain unclear. While ionizing radiation is the only one well-known risk factor for thyroid cancer, the significance of some others remains unclear. The aim of our review was to discuss some not completely known pathophysiological mechanisms involved in thyroid oncogenesis as hypothyroidism, mutations of genes regulating cell proliferation, thyroid autoimmunity and pregnancy and to describe pathophysiological background of some ultrasound markers of thyroid cancer (size, echogenicity, vascularization, calcifications and stiffness). Better knowledge in this field is crucial for development of novel diagnostic techniques and therapeutic approaches. For example, the analysis of BRAF, RAS and other mutations in cytological samples may help to distinction between follicular thyroid carcinoma and follicular thyroid adenoma and may significantly decrease the number of unnecessary surgery among patients with thyroid nodules. Alternatively, the different malign cells growth, angiogenesis, destructions of thyroid follicles, reparative changes, growth retardation, fibrosis and increased interstitial fluid pressure implicate the typical ultrasound appearance of papillary thyroid cancer (hypoechoogenicity, irregular vascularization, microcalcifications, stiffness) which is essential to catch the

suspicious nodules on the basis of their ultrasound appearance among large amount of benign nodules.

### Key words

Thyroid nodule • Thyroid cancer • Hypothyroidism • Thyroid autoimmunity • BRAF mutation • RAS mutation • Thyroid ultrasound • Microcalcifications • Thyroid elastography • Pregnancy

### Corresponding author

J. Krátký, Third Department of Medicine, First Faculty of Medicine, Charles University and General University Hospital, U Nemocnice 1, 128 08 Prague 2, Czech Republic. Fax: +420224919780. E-mail: [jan.kratky@vfn.cz](mailto:jan.kratky@vfn.cz)

With increasing resolution of modern ultrasound equipment the prevalence of thyroid nodules rises up to 76 % (Ferraz *et al.* 2011) while, risk of malignancy is distinctly lower (5-15 %) (Cooper *et al.* 2009). The most common is papillary thyroid carcinoma (PTC) which represents 87 % of thyroid malignancies (Kamran *et al.* 2013). Over the last 40 years, the incidence of PTC has almost tripled in US population, predominantly due to microcarcinomas ( $\leq 1$  cm) (Davies *et al.* 2002). Although there are several risk factors of thyroid cancer and several clinical, ultrasound, biochemical and molecular diagnostic markers (Table 1), the exact mechanisms of thyroid oncogenesis and the linkage between thyroid nodule ultrasound appearance and its biological character remain unclear. While ionizing radiation is the only one good proved risk factor for thyroid cancer, the

significance of some others remains unclear. In the first part of the review some not completely known pathophysiological mechanisms involved in thyroid oncogenesis as hypothyroidism, mutations of genes regulating cell proliferation, thyroid autoimmunity and

pregnancy are discussed and the second part is aimed to describe pathophysiological background of some ultrasound markers of thyroid cancer (size, echogenicity, vascularization, calcifications and stiffness).

**Table 1.** Clinical, ultrasound, biochemical and molecular markers of thyroid cancer.

Clinical	Ultrasound	Biochemical and molecular
History of head or neck irradiation	Diameter >1-2 cm	TSHR-mRNA in peripheral blood
Hoarseness or dysphonia, dysphagia, and dyspnea	Hypoechogenicity	Increased calcitonin serum level
Presence of cervical lymphadenopathy	Increased intra-nodular vascularization	BRAF, RAS, RET/PTC mutations in FNAC samples
Present of thyroid cancer in first degree relative	Irregular margins	
Multiple endocrine neoplasia syndrome 2	Microcalcifications	
Age under 20 or over 70 years	Absence of hypoechoic halo	
Pregnancy	Higher stiffness measured by elastography	
Accumulation of FDG on PET scanning		

PET: positron emission tomography, FDG: Fluorodeoxyglucose, TSHR-mRNA: messenger RNA of thyrotropin receptor, FNAC: fine needle aspiration cytology.

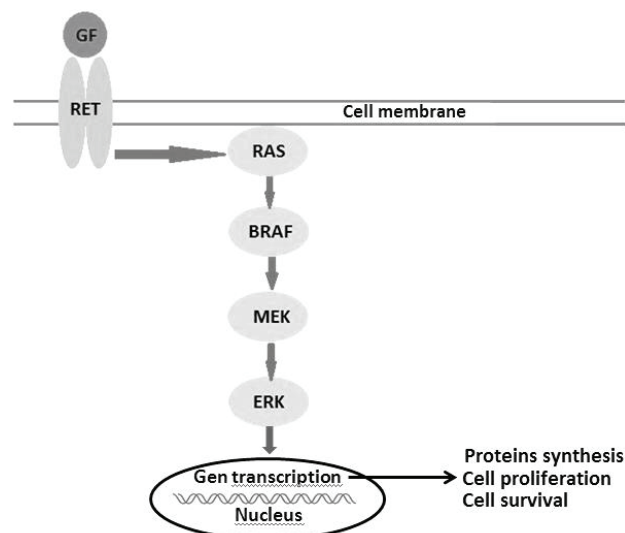
## Hypothyroidism

Hypothyroidism is well-known stimulator of thyroid growth. In peripheral hypothyroidism thyroid hormone synthesis and production and thyroid follicular cells proliferation are mediated by secretion of thyroid stimulating hormone (TSH) in pituitary gland. Physiologically, activation of the TSH receptor by binding of TSH induces intracellular production of cyclic AMP (cAMP) by adenylyl cyclase. The higher level of cAMP activates c-AMP-dependent protein kinase A, which subsequently phosphorylates its substrates. One of them is nuclear factor CREB, which activates the transcription of genes, which are among other responsible for thyroid cells proliferation (Kondo *et al.* 2006). This signaling cascade is analogically responsible for the thyroid growth in hypothyroidism and also well-differentiated thyroid cancer usually preserves this dependence. The levothyroxine suppression treatment in patient after thyroidectomy for differentiated thyroid carcinoma is based on the tumor cells growing inhibition by suppressed TSH level (Biondi *et al.* 2005, Fiore *et al.*

2009). Moreover, a raising risk of malign thyroid nodule with increasing TSH level, and higher TSH level among patients with disease recurrence or progression have been reported (Boelaert *et al.* 2006). Consistently, thyroid nodules with autonomous thyroid hormone secretion (“toxic nodules”) and TSH serum levels <0.4 mIU/l were associated with significantly lower probability of thyroid cancer (Fiore *et al.* 2009) and this mild hyperthyroidism patient may be a protective factor against the development of PTC. It seems to be reasonable to maintain TSH level rather in the lower part of normal range in the patients with thyroid nodules presenting other risk factors of PTC, e.g. autoimmune thyroiditis, previous neck irradiation, pregnancy etc.

## Molecular changes

Mutations of genes regulating cell cycle, cell proliferation and apoptosis certainly play a crucial role in thyroid oncogenesis. Main molecular changes involved in thyroid oncogenesis are BRAF and RAS point mutations and RET-PTC and PAX8/PPAR-gamma rearrangements.



**Fig. 1.** RAS/RAF/MEK signaling pathway. GF: growth factor, RET: RET receptor with tyrosine kinase activity, RAS: GTP binding RAS protein with kinase activity, BRAF: BRAF protein with serine-threonine kinase activity, MEK: MEK protein with kinase activity, ERK: ERK proteins with kinase activity, activates the nuclear transcription by phosphorylation.

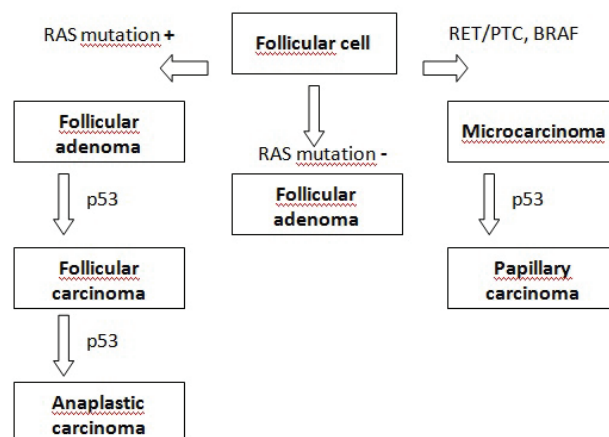
BRAF is a cytoplasmic serine-threonine kinase involved in RAS/RAF/MEK signaling pathway (Fig. 1). Normally the BRAF kinase is activated by linking of RAS protein and it triggers of the whole signaling cascade, which leads to increased growth and cell proliferation. Most proven BRAF V600E mutation leads to permanent phosphorylation activity of the BRAF protein, independent on the binding of RAS protein. Schulten *et al.* (2012) found activated mutation of BRAF gen in 72 of 115 (63 %) PTCs. Cantara *et al.* (2010) analyzed 235 FNAC samples and proved 33 cases of BRAF mutations. All the BRAF mutations were associated with the diagnosis of PTC. Similarly RET/PTC rearrangement (RET/PTC) was found only in patients with PTCs in this study (Cantara *et al.* 2010).

RET is the proto-oncogene, located at chromosome 10, coding cell membrane receptor with tyrosine kinase activity, which after binding of its ligand activates among others the RAS/BRAF/MEK pathway. In some PTCs the RET gen is fused with different gen. At least 11 types of RET/PTC variants have been already isolated (Santoro *et al.* 2006, Marotta *et al.* 2011). The resulting chimeric protein lacks its extracellular and transmembrane domain but has a permanent phosphorylation activity (Marotta *et al.* 2011).

Another common mutation in the aforementioned signaling pathway is the activating mutation of RAS gene. It was found not only in thyroid malignancies but also in benign follicular adenomas

(FTA) (Cantara *et al.* 2010). However, the presence of RAS mutation in FTA may increase the risk of later progression to follicular thyroid carcinoma (FTC).

It seems that the molecular steps in the carcinogenesis are different in FTC and PTC. Direct inception as microcarcinoma is supposed in PTC, whereas FTC probably develops from FTA (Fig. 2).



**Fig. 2.** Hypothetical carcinogenesis of different types of thyroid cancer (adapted Fuchshuber *et al.* 1998). RAS mutation + : presence of mutation of RAS oncogene, RAS mutation - : absence of mutation of RAS oncogene, RET/PTC: presence of RET/PTC rearrangement, BRAF: presence of BRAF oncogene mutation, p53: presence of tumor suppressor protein p53 mutation.

That advance in thyroid nodules and cancer research allowed introducing of further diagnostic tools as molecular analysis of fine needle aspiration cytology (FNAC) samples. Since 2009 the revised guidelines of American Thyroid Association (ATA) recommended to consider the molecular analysis of FNAC samples, if the cytological result is indeterminate. Although cytology and histology remain the gold standard for diagnosis of thyroid malignancies, molecular analysis of FNAC samples may help in the management of patients with indeterminate cytology, in which based on cytology cannot be differentiated between FTC and FTA. The surgery should be chosen in patient with RAS or any other risk mutation in cytology sample.

## Thyroid autoimmunity

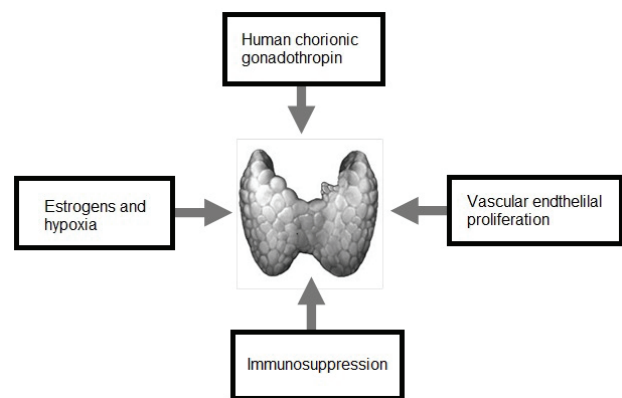
The association between Hashimoto thyroiditis (HT) and PTC is a long-debated question. Some experts even consider HT to be a risk factor for the development of PTC. Indeed, PTC and HT share some epidemiological (exposure to ionizing radiation, higher incidence in

women and areas with high dietary iodine intake) and molecular features (Weetman *et al.* 2004, Cunha *et al.* 2011). The results of a recently published meta-analysis (Lee *et al.* 2013) involving a total of 10648 PTCs demonstrated a significant association between histologically proved HT and PTC. The HT was found in 2471 (23.2 %) with PTC. Interestingly, PTCs with coexisting HT were associated with longer recurrence-free survival, absence of extrathyroidal invasion and absence of lymph node metastasis. An explanation might be an enhanced immune antitumor activity in patients with HT. This idea is also supported by the frequent finding of noninvasive, capsulated microPTCs in thyroid autopsies with HT (Ferraz *et al.* 2011). The HT includes the formation of proliferating nodules as well as cytological alterations and nuclear modification similar to PTC (Cunha *et al.* 2011). On the contrary, it must be noted that an inflammatory changes occur in the majority of tumors in response to the presence of pathological tissue and there is no relevant evidence of causal link between HT and PTC so far. One hypothesis is that development of inflammatory process leads to depletion of follicular thyroid cells and their replacement by mononuclear cells producing chemokines, cytokines and growth factors. Most of them are under transcriptional control of the Nuclear factor-kappa B (NF- $\kappa$ B). The activity of NF- $\kappa$ B could spread to the remaining follicular cells and may lead to the tumor inception in susceptible follicular cells (Pacifico *et al.* 2010). Above mentioned RAS/BRAF/MEK signalization pathway plays a key role in thyroid carcinogenesis. The mutations of BRAF gene are mostly associated with PTC, however is not linked with higher frequency of HT (Kim *et al.* 2009). Conversely, RET/PTC, whose product is the ligand-independent kinase at the beginning of the whole pathway, is more often present at PTCs associated with HT and is even found in benign lesions such as HT (Muzza *et al.* 2010). There may be three hypothetic mechanisms of the linkage between RET/PTC and inflammation: 1) chronic inflammation acts as a source of mutagenic agents such as reactive oxygen radicals that damage DNA and increase the likelihood of random creation of RET/PTC rearrangement; 2) the presence of RET/PTC rearrangement may be the source of other pro-inflammatory transcription factors; 3) molecules released by inflammation could sustain the survival of thyroid cells in which RET/PTC rearrangement randomly occurs and thereby enabling acquire additional mutation and thus become resistant to apoptosis (Cunha *et al.* 2011).

## Pregnancy

Prevalence of thyroid nodules among pregnant women is 9-34 %. About 12-15 % of thyroid nodules discovered in pregnancy can be malignant, predominantly owing to papillary (micro)carcinomas. It is either similar to or possibly greater than seen in general population (De Groot *et al.* 2012, Jiskra *et al.* 2014). About 10 % of thyroid cancers occurring during the reproductive years are diagnosed during pregnancy or early after delivery (Gibelli *et al.* 2011). A history of one or more pregnancies is associated with a small increase in the risk of thyroid cancer (relative risk 1.8) (McTiernan *et al.* 1984). Moreover, thyroid cancer diagnosed during pregnancy may be associated with a poor prognosis as compared with tumors that developed in non-gravid periods (Alves *et al.* 2011, Mazzaferri *et al.* 2011).

Pathophysiological background of increased risk of thyroid cancer development and progression in pregnancy is unknown. The mechanisms most frequently discussed are human chorionic gonadotropin (hCG) and estrogen stimulation, increased vascularity, and lack of immune surveillance of cancer (Alves *et al.* 2011) (Fig. 3).



**Fig. 3.** Main factors influencing oncogenesis and tumor progression in thyroid gland during pregnancy.

### Human chorionic gonadotropin

Human chorionic gonadotropin (hCG) belongs to the family of glycoprotein hormones with the structural homology not only in the hCG and TSH molecules (identical  $\alpha$ -subunit) but also in their receptors. This homology suggests the basis for the reactivity of hCG with the TSH receptor (Yoshimura *et al.* 1995, Voigt *et al.* 2007). At the time of the peak hCG levels in physiological pregnancy, serum TSH levels fall and bear a mirror image to the hCG peak. Maternal thyroid gland

secretes more thyroid hormone during early pregnancy in response to the thyrotropic activity of hCG that overrides the operation of hypothalamic-pituitary-thyroid feedback system (Hershman *et al.* 2004, Alves *et al.* 2011). Analogically, hCG is the most potent stimulator of thyroid growth in the first trimester of pregnancy. Hence, in susceptible thyroid follicular cells (e.g. in cells with BRAF and RAS mutations or RET/PTC and PAX8-PPAR gamma rearrangements) excessive hCG stimulation may lead to inception of rapid progression of cancer.

### *Estrogens*

Estrogens with their receptors may play role in the thyroid oncogenesis, reprogramming and progression (Tafani *et al.* 2014). Indirect estrogen effect is increasing the thyroxine binding globulin (TBG), direct effect on cellular signaling is mediated classically after the binding estradiol (E2) on two soluble intracellular estrogen receptors ER $\alpha$  (ESR1) and ER $\beta$  (ESR2), when ERs form stable dimers that interact with specific sequences called estrogen response elements (EREs) and initiate the transcription of target genes. Additionally, a rapid signaling such as activation of kinases (e.g. phosphatidylinositol 3-kinase) and phosphatases, an increase in ion fluxes across membranes and a transmembrane intracellular non-classical ER mediating with a G protein-coupled receptor (GPCR) has been described in human follicular thyroid carcinoma cell lines *in vitro* (Santin *et al.* 2011).

The important role play estrogen receptors ER $\alpha$  and ER $\beta$  in thyroid stem and progenitor cells with eight times higher expression levels of ER $\alpha$  mRNA compared with the differentiated thyrocytes. The levels are higher in younger women than in older women or men (Horn-Ross *et al.* 2011, Santin *et al.* 2011). The proliferation and growth of thyroid cancer cells are promote by an ER $\alpha$  agonist, in contrast to ER $\beta$  that would promote apoptotic actions and other suppressive functions. Therefore, ER $\alpha$ /ER $\beta$  ratio could have an important role in the pathophysiology of thyroid cancer, similar to that postulated for breast cancer (Santin *et al.* 2011). Furthermore, 17-beta-estradiol significantly increased the expression of Cyclin D1 in a human thyroid carcinoma cell line lacking endogenous TSH receptor (Santin *et al.* 2011). Estrogen-responsive regulatory region of Cyclin D1 regulates the cell progression mediated by the facilitating G1 to S phase transition. Its expression has been associated with an aggressive behavior of papillary

micro-carcinoma (more than 90 % of the metastasizing micro-carcinomas expressed Cyclin D1 (Khoo *et al.* 2002). In contrast, TSH-induced differentiation of progenitor cells was significantly inhibited by E2. Also, estrogens stimulated the growth with a lower extent than other growth factors and simultaneously inhibited the differentiation of thyroid nodule-derived stem/progenitor cells (Xu 2013). Despite of the experimental evidence, the vast majority of clinical studies has not proved the use of oral contraceptives or other exogenous estrogens to be associated with higher risk of thyroid cancer or its unfavourable prognosis (Mazzaferri *et al.* 2011). Only in one study an increased risk of thyroid cancer with the number of pregnancies was observed, but only in women who prematurely stopped lactation (Mack *et al.* 1999).

Estrogen aids in angiogenesis of various tumors during hypoxic conditions, however the role of estrogen within the hypoxic environment of thyroid cancer is not known. Hypoxia with estrogens modulate the hypoxia inducible factor-1 (HIF-1) signaling which is abrogated by the anti-estrogen fulvestrant and the HIF-1 inhibitor YC-1 (3-(5'-hydroxymethyl-2'-furyl)-1-benzylindazole) (Rajoria *et al.* 2013). HIF-1 inhibitor can abolish migration and tubulogenesis of human umbilical vein endothelial cells (HUVECs) in thyroid cancer cells. HIF-1 and NF- $\kappa$ B are two transcription factors very frequently activated in tumors and involved in tumor growth, progression, inflammatory-reparative response, and resistance to chemotherapy (Tafani *et al.* 2014).

### *Increased vascularization*

Increased vascularization of thyroid parenchyma, which can be visualized by color/power doppler ultrasound is typical finding in pregnancy. It is mediated predominantly by hCG and VEGF stimulation. High tumorigenic potential is associated with an elevated vascular endothelial growth factor (VEGF) expression in human thyroid tumor cell lines. In contrast, placental growth factor (PIGF) expression is severely down regulated in the majority of thyroid tumor cell lines and in tumors (Viglietto *et al.* 1995). Both the VEGF receptors (FLT-1 and flk/KDR) are expressed in endothelial cells that line tumor-embedded micro-vascular vessels, suggesting that VEGF but not PIGF, contributes to thyroid tumor development (Viglietto *et al.* 1995). VEGF and hCG mediated vascularization of thyroid parenchyma may facilitate cancer cell angiogenesis and contribute to the worse prognosis of thyroid cancer diagnosed in pregnancy.

### *Changes of immune system in pregnancy*

Several changes in immune system which can support development and progression of malignancy were described in pregnancy. They include immune tolerance to fetus as the semi-allograft, shift T1 helper lymphocytes (Th1) to T2 helper lymphocytes (Th2), immunosuppressive effect of progesteron, and tolerogenic effect of regulatory T cells. The important fact is that 40 % of decidual cells are cells of the innate immune system (NK cells, macrophages, dendritic cells and T reg cells). Regulatory T cells and Th2 cells are important mediators of tolerance in both pregnancy and cancer. Expression of human leucocyte antigen G (HLA-G) on trophoblast cells and cancer cells has important immunomodulatory effects. Its expression correlated amount of invasive, interstitial and endovascular extravillous trophoblast cells. The role of HLA-G is to suppress cytolytic killing by both NK and cytotoxic T cells, to induce apoptosis of immune cells, to regulate cytokine production in blood mononuclear cells, and to reduce stimulatory capacity and impair maturation of dendritic cells (Holtan *et al.* 2009).

### **Pathophysiological background of ultrasound markers of thyroid cancer**

Increasing quality and resolution of modern ultrasound equipment make thyroid ultrasound the key non-invasive technique to predict biological nature of the thyroid nodule.

#### *Size*

The size of nodules itself as a risk factor of malignancy is questionable. Whereas benign adenomas may reach large proportion, PTC is often found as microcarcinoma (in up to one third of adult thyroid autopsy) (Vanderpump *et al.* 2011). So far, nodules >1 cm in diameter were considered to have malign potential and should be referred to US-FNAC. Recently, in a large study including 7348 thyroid nodules >1 cm in diameter, Kamran *et al.* (2013) referred a higher risk of thyroid carcinoma among nodules >2 cm in comparison to nodules 1-2 cm in diameter. Unlike PTC, the frequency of the FTC was rising with increasing size of the nodules. It implies that whereas PTC is largely predetermined at its inception and does not transform with growth, the FTC develops from FTA only if expands to certain size (Kamran *et al.* 2013). One explanation is that nodule growth increases risk of secondary genomic mutations

that transform FTA to FTC. The second one is that the histological hallmarks of FTC (angioinvasion and/or capsular invasion) may occur only when FTA reaches certain cellular number. The idea of transforming FTA to FTC is also supported by findings of known risk oncogenic mutation (RAS, PAX 8/PPARgamma) in FTA (Suarez *et al.* 1990, Cantara *et al.* 2010). The FTA with RAS mutation could be the precursors of FTC and may be best characterized as “carcinoma *in situ*” (Nikiforof *et al.* 2011). Another attractive hypothesis of FTA malignant transformation is the increased activity of metalloproteinase-9, the enzyme which degrades collagen-4. Collagen-4 is an essential compound of basal membrane and its degradation may allow the cell infiltration. Friguglietti *et al.* (2000) found significantly higher immunohistochemical positivity of metalloproteinase-9 in the FTC cells compared to the FTA. Apparently, the nodules with cytological finding follicular lesion of indeterminate significance should be carefully monitored for the growth progression. The presence of progression may indicate risk of developing FTC and the patient should be refer to surgery. In fact, the size of thyroid nodule as a predictor of thyroid malignancy may be relevant in follicular lesions, whereas the risk of PTC is probably equal in small and large lesions.

#### *Vascularization*

It is well known fact that increased intra-nodular vascularity proven on Doppler ultrasound is a risk factor for thyroid carcinoma especially for PTC. Angiogenesis plays an important role in tumor growth and proliferation. Akslen *et al.* (2000) analyzed histological samples of 128 PTC and they found 3.14 times higher microvessel density in the carcinomas, compared to normal surrounding thyroid tissue, however increased tumor vascularization was not associated with a poorer prognosis. They suggest that this may be due to the fact that PTC unlike the FTC locally spread primarily through lymphatic veins. However, there are also papers demonstrating increasing microvessel density with rising invasiveness of PTC. According the results of Chinese study by Liang *et al.* (2006) the density of lymphatic vessels and also microvessels was the lowest in the group of microPTC ( $\leq 1$  cm), raised in the tumors >1 cm and was the highest in the group of metastatic PTC. Consistently, the expression of vascular endothelial growth factor C (VGEF-C) was increasing in these groups in the same way.

Increased neovascularization in PTC seems to be caused by an imbalance between pro-angiogenic and anti-angiogenic factors. Tanaka *et al.* (2002) analyzed the expression patterns and levels of several anti- and pro-angiogenic factors and its receptors in 75 PTCs and found that VEGF expression strongly positively correlated with the other pro-angiogenic factors (VEGF-C, Angiopoietin-2, and Tie-2) and their higher expression was associated with increased microvascular density. Conversely, Thrombospondin-1 (antiangiogenic factor) expression correlated with the degree of invasion negatively. They counted VEGF/Thrombospondin-1 and Angiopoietin-2/Thrombospondin-1 ratios that significantly correlated with the degree of tumor infiltration (Tanaka *et al.* 2002). Presence of Doppler signal in the central part of the nodule surely increases the risk of malignancy. However, current high-sensitive ultrasound devices can receive Doppler signals also of regular intra-nodular vascularization of benign nodule and to distinguish it from the irregular chaotic vascularization in malign nodules may not be always easily possible.

#### *Echogenicity and nodule margin*

PTC ultrasound image typically appears as an irregular hypoechoic nodule. The irregular shape is due to the uneven tumor cells proliferation. The cause why PTC is hypoechoic is still not clear. We suggest it could be caused by the lack of follicular tissue arrangement that is specific for thyroid gland and that implies the typical hyperechoic picture of the healthy thyroid parenchyma in comparison to neck muscles and other surrounding tissues. The solid PTC cell mass, unlike the normal follicles, does not contain as many interface with different acoustic impedance. This may reduce the ultrasound reflection in the PTC. Nevertheless, majority of the thyroid nodules are hypoechoic in comparison with the normal thyroid tissue, but only marked hypoechogenicity seems to be suspect. The evaluation of the nodules echogenicity is often affected by the physician's experience and his subjective view. Few years ago the automatic texture analyzer was successfully used to distinguish between the texture of normal thyroid gland and thyroiditis in Czech Republic (Smutek *et al.* 2003). Similarly, automatic analyzer evaluating thyroid nodules echogenicity could be developed and it could eliminate the influence of the examiner.

#### *Calcifications*

The presence of calcifications in thyroid

nodules, regardless of their appearance, may be associated with higher risk of malignancy (Taki *et al.* 2004, Reading *et al.* 2005). Macrocalcifications are large ( $>2$  mm) hyperechoic spots that cause acoustic shadow and may be present both in benign and malign nodules. They originate in areas of tiny hemorrhages and destructions in thyroid nodules as a result of reparative changes with precipitations of calcium salts (dystrophic calcifications). Microcalcifications are visualized as small ( $\leq 2$  mm) hyperechoic points without acoustic shadow. They are associated with the papillary (nipple-like) histomorphology and occur very common in malign nodules with frequency 26-70 % (Frates *et al.* 2006, Kwak *et al.* 2011), but are relatively rare in benign lesions. Histopathologically microcalcifications are „psammoma bodies“ (PBs). The term is derived from the Greek word “psammos” meaning “sand”. Despite numerous ancillary studies over a span of three and half decades, formation of PBs bodies remains a poorly understood mechanism. Ultrastructural study of PTC has shown that thickening of the base lamina in vascular stalk of neoplastic papillae followed by thrombosis, calcification, tumor cell necrosis and collagen production by neoplastic cells to formation of PBs (Johannessen *et al.* 1980, Das *et al.* 2009). It is suggested that rather than being the outcome of dystrophic calcification of dead or dying tissue, PBs may indeed represent an active biologic process ultimately leading to degeneration/death of tumor cells and retardation of growth of the neoplasm. It may also serve as a barrier against the spread of neoplasm (Das *et al.* 2009). This is in concordance with the common clinical finding that microcalcifications are most frequently found in small ( $<2$  cm) papillary thyroid cancers (Shi *et al.* 2012) with slow non-invasive tumor growth and good clinical prognosis. Fortunately, microcalcifications can be easily confused with dense colloid aggregations (in benign “colloid” nodules) or with the fibrosis of the tissue (in Hashimoto's thyroiditis). In contrast to dense colloid aggregations which vibrate due to ultrasonic wave and cause an artifact called “comet tail”, the microcalcifications stay motionless and in contrast to fibrosis they are separate structures and do not form irregular stripes, connecting with each other (Lewinski and Adamczewski 2013). A novel ultrasound diagnostic technique “MicroPure” was recently developed by Toshiba Medical System Corporation (<http://www.toshiba-medical.eu/en/Our-Product-Range/Ultrasound/Technologies/MicroPure2/>) aimed to distinguish microcalcifications from the artifacts and



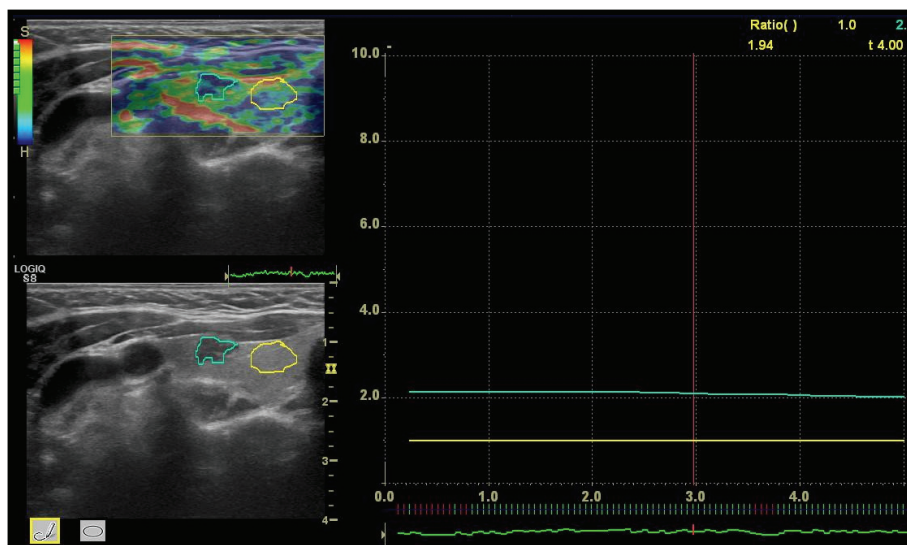
fibrosis. Usefulness of MicroPure imaging in measuring of microcalcifications was demonstrated both in breast and thyroid lesions (Sankaye *et al.* 2010, Ciledag *et al.* 2012).

#### Nodule stiffness

Uncontrolled proliferation and irregular growth of malign cells may cause a higher stiffness of tumor mass compared to normal thyroid tissue. On the higher stiffness of the carcinomas may contribute some of the following factors: Increased interstitial fluid pressure (IFP), which has been observed in many of human carcinomas and reach up to 60 mm Hg. The mechanism of elevated IFP is not exactly known. It involves an increased permeability of the defect tumor blood vessels. Leak of the plasma proteins which are not effectively drained through the pathological lymphatic vessels increased interstitial oncotic pressure. The leakiness of tumor vessels might be due to the overproduction of VEGF by the tumor cells, which has been shown to increase permeability, and due to the tumor stromal

infiltration by the activated macrophages and other immune cells and by their cytokines as well. Moreover the extracellular matrix of the tumor contains much denser collagen fiber network and increased number of the fibroblast. Therefore, the tumor is more rigid in comparison with normal tissue (Heldin *et al.* 2004). The presence of hard calcification, fairly typical for thyroid carcinoma, makes the tumor stiffer as well.

Tissue elasticity can be determined by elastography, the relatively new ultrasound modality. It was first introduced in 1991 by Orphir (Orphir *et al.* 1991). It is assumed that higher stiffness may predict a higher risk of thyroid cancer. Actually there are two different types of elastography – Real time (strain) elastography (RTE) and Shear wave elastography (SWE). Both methods do not differ only by their principle but also by their output. While SWE can directly quantified tissue elasticity using the Young's modulus of elasticity, RTE shows only the relative distribution of elasticity displayed by map of relative elasticity distribution, called elastogram (Fig. 4).



**Fig. 4.** Elastogram and strain-ratio (2.1) of papillary thyroid carcinoma.

According to a meta-analysis published in 2010 which involved a total of 639 nodes from eight studies, RTE reached the sensitivity 92 % and specificity of 90 % in detecting thyroid malignancies (Bojunga *et al.* 2010). Recently, high negative predictive value of quantitative RTE for thyroid malignancy (99.1 % and 97.2 % respectively) was found (Azizi *et al.* 2013, Mehrota *et al.* 2013). Higher reproducibility of RTE can be achieved by semi-quantitative analysis using strain ratio (the ratio of elasticity of the nodule as compared to surrounding normal thyroid tissue) (Cantisani *et al.* 2014). Although

there is lack of information about usefulness of semi-quantitative RTE in differential diagnosis of thyroid nodules, our own experiences showed promising results. To date, we determined the strain-ratio of 35 thyroid nodules (10 malign and 25 benign) in comparison to the surrounding thyroid tissue, to the carotid artery and to the neck muscles. In all three categories we found significant differences of strain-ratio between benign and malignant lesions (unpublished results).

For all that, there are several limitations of elastography: cystic nodules appear to be falsely stiff due



to the non-compressible fluid content (Bathia *et al.* 2011), the fibrotic/atrophic involution in the benign lesions may increase the stiffness of the benign nodules (Cantisani *et al.* 2014) etc. Bojunga *et al.* (2010) reported that most of the false negative results of RTE were FTC, because FTC might be soft and may be considered as a benign nodule. Therefore, elastography seems to be useful predominantly for diagnosis of PTC.

## Conclusion

It seems that persistently elevated serum levels of TSH in patients with thyroid nodules may participate in cancer genesis. However, the stimulation of the growth of already present latent microcarcinomas then real cancer inception is the pathophysiological mechanism. On the other hand, hyperthyroidism linked with TSH suppression may act as a protection factor for thyroid cancer development.

The causal relationship between thyroid cancer and thyroid autoimmunity remains still unclear. Epidemiological association of papillary thyroid cancer and thyroid autoimmunity was reported, however the causal relationship is not adequately proved so far. Moreover, even better prognosis of patients with coexisting HT and PTC was reported. Hypothetical mechanisms of causal relationship between thyroid cancer and thyroid autoimmunity may be the replacement of thyroid follicular cells by mononuclear cells producing several growth factors, production of reactive oxygen radicals that damage DNA and better survival of thyroid cells with RET/PTC rearrangement in chronic autoimmune inflammation.

Human chorionic gonadotropin and estrogen stimulation, increased vascularization, and lack of immune surveillance of cancer are the most important mechanisms that cause the increased risk of thyroid cancer development and progression in pregnancy.

Mutations of genes regulating cell cycle, cell proliferation and apoptosis certainly play a crucial role in thyroid oncogenesis. However, it seems that the molecular steps in the carcinogenesis are different in PTC (direct inception as microcarcinoma) and FTC (probably develops from FTA). The different origin and development contribute to different diagnostic possibilities of both carcinomas as well. Except for the size, the most of the above-described clinical, ultrasound and molecular characteristics are especially associated with PTC and its diagnostic options are quite sufficient

now. PTC is assumed to arise *de novo* and not by the oncogenesis in already pre-existing benign nodule. Thanks to that, the PTC has a relatively typical ultrasound appearance (hypoechoogenicity, irregular vascularization, irregular nodule margin, microcalcifications and stiffness). Probably, the different character of malignant cells growth, angiogenesis, destruction of thyroid follicles, reparative changes, growth retardation, fibrosis and increased interstitial fluid pressure, implicate the typical ultrasound appearance of PTC. On the contrary, the size of nodule itself as a risk factor of PTC is problematic. As above mentioned, PTC is largely predetermined at its inception and does not transform with growth, whereas the FTC develops from follicular thyroid adenoma (FTA) only if expands to certain size. Therefore, the size as a risk factor for malignancy may be used perhaps in follicular lesions, but not in PTC.

In the future, especially the pathogenesis of FTC, which could help in the development of innovative methods to distinguish between FTC and FTA, should be focused on. Based on the ultrasound appearance and cytological examination is not possible to distinguish between both pathologies. Currently, only the histological examination after diagnostic surgery with the proved angioinvasion or invasion through the nodule capsule may distinguish between the both. Currently, the study of certain tumor-specific mutations is the most promising way. It seems that RAS mutation could be the risk factor of the FTA transformation into FTC in the future.

## Conflict of Interest

There is no conflict of interest.

## Acknowledgement

Supported by Research Project of Charles University Prvok P25.

## Abbreviations

ATA, American Thyroid Association; BRAF, BRAF protein (oncogene); cAMP, cyclic adenosine monophosphate; E2, estradiol; EREs, estrogen response elements; FNAC, fine needle aspiration cytology; FTA, follicular adenoma; FTC, follicular thyroid carcinoma; GPCR, G protein-coupled receptor; hCG, human chorionic gonadotropin; HIF-1, hypoxia inducible factor-1; HLAG, human leukocyte antigen; HT, Hashimoto thyroiditis; IFP, increased interstitial fluid pressure; NF-kb, nuclear factor-kappa B; PBs,

psammoma bodies; PIGF, placental growth factor; PTC, papillary thyroid carcinoma; RAS, RAS protein (oncogene); RET/PTC, RET/PTC rearrangement; RTE, real time elastography; SWE, shear wave elastography; TBG, thyroxin binding globulin; Th1, T1 helper

lymphocytes; Th2, T2 helper lymphocytes; TSH, thyroid stimulating hormone; US-FNAC, ultrasound guided fine needle aspiration cytology; VEGF, vascular endothelial growth factor; VEGF-C, vascular endothelial growth factor C.

## References

- AKSLEN LA, LIVOLSI VA: Increased angiogenesis in papillary thyroid carcinoma but lack of prognostic importance. *Hum Pathol* **31**: 439-442, 2000.
- ALVES VG, SANTIN PA, FURLANETTO WT: Prognosis of thyroid cancer related to pregnancy: a systematic review. *J Thyroid Res* **10**: 1-5, 2011.
- AZIZI G, KELLER J, LEWIS M, PUETT D, RIVENBARK K, MALCHOFF C: Performance of elastography for the evaluation of thyroid nodules: a prospective study. *Thyroid* **23**: 734-740, 2013.
- BIONDI B, FILETTI S, SCHLUMBERGER M: Thyroid-hormone therapy and thyroid cancer: a reassessment. *Nat Clin Pract Endocrinol Metab* **1**: 32-34, 2005.
- BHATIA KS, RASALKAR DP, LEE YP, WONG KT, KING AD, YUEN HY, AHUJA AT: Cystic change in thyroid nodules: a confounding factor for real-time qualitative thyroid ultrasound elastography. *Clin Radiol* **66**: 799-807, 2011.
- BOELAERT K, HORACEK J, HOLDER RL, WATKINSON JC, SHEPPARD MC, FRANKLYN JA: Serum thyrotropin concentration as a novel predictor of malignancy in thyroid nodules investigated by fine-needle aspiration. *J Clin Endocrinol Metab* **91**: 4295-4301, 2006.
- BOJUNGA J, HERRMANN E, MEYER G, WEBER S, ZEUZEM S, FRIEDRICH-RUST M: Real-time elastography for the differentiation of benign and malignant thyroid nodules: a meta-analysis. *Thyroid* **20**: 1145-1150, 2010.
- CANTARA S, CAPEZZONE M, MARCHISOTTA S, CAPUANO S, BUSONERO G, TOTI P, DI SANTO A, CARUSO G, CARLI AF, BRILLI L, MONTANARO A, PACINI F: Impact of proto oncogene mutation detection in cytological specimens from thyroid nodules improves the diagnostic accuracy of cytology. *J Clin Endocrinol Metab* **95**: 1365-1369, 2010.
- CANTISANI V, LODISE P, GRAZHDANI H, MANCUSO E, MAGGINI E, DI ROCCO G, D'AMBROSIO F, CALLIADA F, REDLER A, RICCI P, CATALANO C: Ultrasound elastography in the evaluation of thyroid pathology. Current status. *Eur J Radiol* **83**: 420-428, 2014.
- CILEDAG N, ARDA K, ARIBAS BK, AKTAS E, KÖSE SK: The utility of ultrasound elastography and MicroPure imaging in the differentiation of benign and malignant thyroid nodules. *AJR Am J Roentgenol* **198**: 244-249, 2012.
- COOPER DS, DOHERTY GM, HAUGEN BR, KLOOS RT, LEE SL, MANDEL SJ, MAZZAFERRI EL, McIVER B, PACINI F, SCHLUMBERGER M, SHERMAN SI, STEWARD DL, TUTTLE RM: Revised American Thyroid Association management guidelines for patients with thyroid nodules and differentiated thyroid cancer. *Thyroid* **19**: 1167-1214, 2009.
- CUNHA LL, FERREIRA RC, MARCELLO MA, VASSALLO J, WARD LS: Clinical and pathological implications of concurrent autoimmune thyroid disorders and papillary thyroid cancer. *J Thyroid Res* **2011**: 1-13, 2011.
- DAS DK: Psammoma body: a product of dystrophic calcification or of a biologically active process that aims at limiting the growth and spread of tumor? *Diagn Cytopathol* **37**: 534-541, 2009.
- DAVIES L, WELCH HG: Increasing incidence of thyroid cancer in the United States, 1973-2002. *JAMA* **295**: 2164-2167, 2006.
- DE GROOT L, ABALOVICH M, ALEXANDER E, AMINO N, BARBOUR L, COBIN R, EASTMAN C, LAZARUS J, LUTON D, MANDEL S, MESTMAN J, ROVET J, SULLIVAN S: Management of thyroid dysfunction during pregnancy and postpartum: an Endocrine Society clinical practice guideline. *J Clin Endocrinol Metab* **97**: 2543-2565, 2012.

- FERRAZ C, ESZLINGER M, PASCHKE R: Current state and future perspective of molecular diagnosis of fine-needle aspiration biopsy of thyroid nodules. *J Clin Endocrinol Metab* **96**: 2016-2026, 2011.
- FIGLIORE E, RAGO T, PROVENZALE M, SCUTARI M, UGOLINI C, BASOLO F, DI COSCIO G, BERTI P, GRASSO L, ELISEI R, PINCHERA A, VITTI P: Lower levels of TSH are associated with a lower risk of papillary thyroid cancer in patients with thyroid nodular disease: thyroid autonomy may play a protective role. *Endocr Relat Cancer* **16**: 1251-1260, 2009.
- FRATES MC, BENSON CB, CHARBONEAU JW, CIBAS ES, CLARK OH, COLEMAN BG, CRONAN JJ, DOUBILET PM, EVANS DB, GOELLNER JR, HAY ID, HERTZBERG BS, INTENZO CM, JEFFREY RB, LANGER JE, LARSEN PR, MANDEL SJ, IDDLTON WD, READING CC, SHERMAN SI, TESSLER FN: Management of thyroid nodules detected at US: Society of Radiologists in Ultrasound consensus conference statement. *Ultrasound Q* **22**: 231-238, 2006.
- FRIGUGLIETTI CU, MELLO ES, CASTRO IV, FILHO GB, ALVES VA: Metalloproteinase-9 immunoexpression and angiogenesis in thyroid follicular neoplasms: relation to clinical and histopathologic features. *Head Neck* **22**: 373-379, 2000.
- FUCHSHUBER P, LOREE TR, DELACURE MD, HICKS WL JR: Differentiated thyroid carcinoma: risk group assignment and management controversies. *Oncology (Williston Park)* **1**: 99-106, 1998.
- GIBELLI B, ZAMPERINI P, PROH M, GIUGLIANO G: Management and follow-up of thyroid cancer in pregnant women. *Acta Otorhinolaryngol Ital* **31**: 358-365, 2011.
- HELDIN CH, RUBIN K, PIETRAS K, OSTMAN A: High interstitial fluid pressure – an obstacle in cancer therapy. *Nat Rev Cancer* **4**: 806-813, 2004.
- HERSHMAN MJ: Physiological and pathological aspects of the effect of human chorionic gonadotropin on the thyroid. *Best Pract Res Clin Endocrinol Metab* **18**: 249-265, 2004.
- HOLTAN GS, CREEDON JD, HALUSKA P, MARKOVIC NS: Cancer and pregnancy: parallels in growth, invasion, and immune modulation and implications for cancer therapeutic agents. *Mayo Clin Proc* **84**: 985-1000, 2009.
- HORN-ROSS LP, CANCHOLA JA, MA H, REYNOLDS P, BERNSTEIN L: Hormonal factors and the risk of papillary thyroid cancer in the California Teachers Study cohort. *Cancer Epidemiol Biomarkers Prev* **20**: 1751-1759, 2011.
- JISKRA J, KRÁTKÝ J, LÍMANOVÁ Z: Thyroid carcinoma in gravidity: case reports (in Czech). *Prakt Gyn* **1**: 47-53, 2014.
- JOHANNESSEN JV, SOBRINHO-SIMÕES M: The origin and significance of thyroid psammoma bodies. *Lab Invest* **43**: 287-296, 1980.
- KAMRAN SC, MARQUSEE E, KIM MI, FRATES MC, RITNER J, PETERS H, BENSON CB, DOUBILET PM, CIBAS ES, BARLETTA J, CHO N, GAWANDE A, RUAN D, MOORE FD JR, POUL K, LARSEN PR, ALEXANDER EK: Thyroid nodule size and prediction of cancer. *J Clin Endocrinol Metab* **98**: 564-570, 2013.
- KHOO CLM, EZZAT S, FREEMAN LJ, ASA LS: Cyclin D1 protein expression predicts metastatic behavior in thyroid papillary microcarcinomas but is not associated with gene amplification. *J Clin Endocrinol Metab* **87**: 1810-1813, 2002.
- KIM SK, SONG KH, LIM SO: Clinical and pathological features and the BRAF mutation in patients with papillary thyroid carcinoma with and without Hashimoto thyroiditis. *Thyroid* **19**: 137-141, 2009.
- KONDO T, EZZAT S, ASA SL: Pathogenetic mechanisms in thyroid follicular-cell neoplasia. *Nat Rev Cancer* **6**: 292-306, 2006.
- KWAK JY, HAN KH, YOON JH, MOON HJ, SON EJ, PARK SH, JUNG HK, CHOI JS, KIM BM, KIM EK: Thyroid imaging reporting and data system for US features of nodules: a step in establishing better stratification of cancer risk. *Radiology* **260**: 892-899, 2011.
- LEE JH, KIM Y, CHOI JW, KIM YS: The association between papillary thyroid carcinoma and histologically proven Hashimoto's thyroiditis: a meta-analysis. *Eur J Endocrinol* **168**: 343-349, 2013.
- LEWINSKI A, ADAMCZEWSKI Z: Decision making for surgery in the suspect thyroid nodule. *Thyroid Int* **1**: 3-18, 2013.

- LIANG QC, WEI QY, FAN SQ: Expression of VEGF-C and angiogenesis, and lymphangiogenesis in papillary thyroid carcinoma. *Zhong Nan Da Xue Xue Bao Yi Xue Ban* **31**: 414-416, 2006.
- MACK WJ, PRESTON-MARTIN S, BERNSTEIN L, QIAN D, XIANG M: Reproductive and hormonal risk factors for thyroid cancer in Los Angeles County females. *Cancer Epidemiol Biomarkers Prev* **8**: 991-997, 1999.
- MAROTTA V, GUERRA A, SAPIO MR, VITALE M: RET/PTC rearrangement in benign and malignant thyroid diseases: a clinical standpoint. *Eur J Endocrinol* **165**: 499-507, 2011.
- MAZZAFERRI LE: Approach to the pregnant patient with thyroid cancer. *J Clin Endocrinol Metab* **96**: 265-272, 2011.
- McTIERNAN MA, WEISS SN, DALING RJ: Incidence of thyroid cancer in women in relation to reproductive and hormonal factors. *Am J Epidemiol* **120**: 423-435, 1984.
- MEHROTRA P, McQUEEN A, KOLLA S, JOHNSON SJ, RICHARDSON DL: Does elastography reduce the need for thyroid FNAs? *Clin Endocrinol (Oxf)* **78**: 942-949, 2013.
- MUZZA M, DEGL'INNOCENTI D, COLOMBO C, PERRINO M, RAVASI E, ROSSI S, CIRELLO V, BECK-PECCOZ P, BORRELLO MG, FUGAZZOLA L: The tight relationship between papillary thyroid cancer, autoimmunity and inflammation: clinical and molecular studies. *Clin Endocrinol (Oxf)* **72**: 702-708, 2010.
- NIKIFOROV YE, OHORI NP, HODAK SP, CARTY SE, LEBEAU SO, FERRIS RL, YIP L, SEETHALA RR, TUBLIN ME, STANG MT, COYNE C, JOHNSON JT, STEWART AF, NIKIFOROVA MN: Impact of mutational testing on the diagnosis and management of patients with cytologically indeterminate thyroid nodules: a prospective analysis of 1056 FNA samples. *J Clin Endocrinol Metab* **96**: 3390-3397, 2011.
- OPHIR J, CÉSPÉDES I, PONNEKANTI H, YAZDI Y, LI X: Elastography: a quantitative method for imaging the elasticity of biological tissues. *Ultrason Imaging* **13**: 111-1134, 1991.
- PACIFICO F, LEONARDI A: Role of NF- $\kappa$ B in the thyroid cancer. *Mol Cell Endocrinol* **321**: 29-35, 2010.
- RAJORIA S, NICOLINI A, HANLY E, GEORGE LA, GELIEBTER J, SHIN JE, SURIANO R, CARPI A, TIWARI KR: Interlinking of hypoxia and estrogen in thyroid cancer progression. *Curr Med Chem* **10**: 1-10, 2013.
- READING CC, CHARBONEAU JW, HAY ID, SEBO TJ: Sonography of thyroid nodules: a "classic pattern" diagnostic approach. *Ultrasound Q* **21**: 157-165, 2005.
- SANKAYE P, PORTER G, DOYLE S: Initial experience with MicroPure, a new ultrasound image processing function to improve calcification visualization. *Breast Cancer Res* **12**: 39, 2010.
- SANTIN PA, FURLANETTO WT: Role of estrogen in thyroid function and growth regulation. *J Thyroid Res* **10**: 1-5, 2011.
- SANTORO M, MELILLO RM, FUSCO A: RET/PTC activation in papillary thyroid carcinoma: European Journal of Endocrinology Prize Lecture. *Eur J Endocrinol* **155**: 645-653, 2006.
- SCHULTEN HJ, SALAMA S, AL-MANSOURI Z, ALOTIBI R, AL-GHAMDI K, AL-HAMOUR OA, SAYADI H, AL-ARADATI H, AL-JOHARI A, HUWAIT E, GARI M, AL-QAHTANI MH, AL-MAGHRABI J: BRAF mutations in thyroid tumors from an ethnically diverse group. *Hered Cancer Clin Pract* **10**: 1186-1197, 2012.
- SHI C, LI S, SHI T, LIU B, DING C, QIN H: Correlation between thyroid nodule calcification morphology on ultrasound and thyroid carcinoma. *J Int Med Res* **40**: 350-357, 2012.
- SMUTEK D, SÁRA R, SUCHARDA P, TJAHHADI T, SVEC M: Image texture analysis of sonograms in chronic inflammations of thyroid gland. *Ultrasound Med Biol* **29**: 1531-1543, 2003.
- SUAREZ HG, DU VILLARD JA, SEVERINO M, CAILLOU B, SCHLUMBERGER M, TUBIANA M, PARMENTIER C, MONIER R: Presence of mutations in all three ras genes in human thyroid tumors. *Oncogene* **5**: 565-570, 1990.
- TAFANI M, DE SANTIS E, COPPOLA L, PERRONE AG, CARNEVALE I, RUSSO A, PUCCI B, CARPI A, BIZZARRI M, RUSSO AM: Bridging hypoxia, inflammation and estrogen receptors in thyroid cancer progression. *Biomed Pharmacother* **68**: 1-5, 2014.
- TAKI S, TERAHATA S, YAMASHITA R, KINUYAD K, NOBARAE K, KAKUDAE K, KODAMAA Y, YAMAMOTOA I: Thyroid calcifications: sonographic patterns and incidence of cancer. *Clin Imaging* **28**: 368-371, 2004.
- TANAKA K, SONOO H, KUREBAYASHI J, NOMURA T, OHKUBO S, YAMAMOTO Y, YAMAMOTO S: Inhibition of infiltration and angiogenesis by thrombospondin-1 in papillary thyroid carcinoma. *Clin Cancer Res* **8**: 1125-1131, 2002.

- 
- VANDERPUMP MP: The epidemiology of thyroid disease. *Br Med Bull* **99**: 39-51, 2011.
- VIGLIETTO G, MAGLIONE D, RAMBALDI M, CERUTTI J, ROMANO A, TRAPASSO F, FEDELE M, IPPOLITO P, CHIAPPETTA G, BOTTI G, ET AL.: Upregulation of vascular endothelial growth factor (VEGF) and downregulation of placenta growth factor (PlGF) associated with malignancy in human thyroid tumors and cell lines. *Oncogene* **11**: 1569-1579, 1995.
- VOIGT V, MAHER G, WOLF HH, SCHMOLL JH: Human chorionic gonadotropin-induced hyperthyroidism in germ cell cancer – a case presentation and review of the literature. *Onkologie* **30**: 330-334, 2007.
- WEETMAN AP: Cellular immune response in autoimmune thyroid disease. *Clin Endocrinol* **61**: 405-413, 2004.
- XU S, CHEN G, PENG W, RENKO K, DERWAHL M: Oestrogen action on thyroid progenitor cells: relevant for the pathogenesis of thyroid nodules? *J Endocrinol* **218**: 125-133, 2013.
- YOSHIMURA M, HERSHMAN MJ: Thyrotropic action of human chorionic gonadotropin. *Thyroid* **5**: 425-434, 1995.
-