

Orthogonal Polarization Spectral Imaging

V. ČERNÝ, Z. TUREK, R. PAŘÍZKOVÁ

University Hospital Hradec Králové, Department of Anesthesiology and Intensive Care,
Czech Republic

Received December 8, 2005

Accepted February 27, 2006

On-line available March 23, 2006

Summary

The microcirculation plays a crucial role in the interaction between blood and tissues both in physiological and pathophysiological states. Despite its critical role in numerous diseases including diabetes, hypertension, sepsis or multiple organ failure, methods for direct visualization and quantitative assessment of human microcirculation at the bedside are limited. Orthogonal polarization spectral (OPS) imaging is a relatively new noninvasive method for assessment of human microcirculation without using fluorescent dyes. Recent clinical studies using OPS imaging in various pathological states have shown a wide spectrum of different clinical applications with evident impact on the diagnosis, treatment or prognosis assessment. Thus, there is a great effort to validate OPS imaging for various clinical purposes. The principles of OPS imaging, validation studies, its advantages, limitations, methods of quantitative assessment and current experience in clinical practice are discussed.

Key words

Microcirculation • Orthogonal polarization • Spectral Imaging

Introduction

The microcirculation plays a crucial role in the interaction between blood and tissue both in the physiological and pathophysiological states. Analysis of microvascular blood flow alterations provides a unique perspective to study processes at the microscopic level in clinical medicine (Fagrell and Intaglieta 1997). Despite the critical role of microcirculation in numerous diseases including diabetes (Tooke 1996), hypertension, sepsis (Lehr *et al.* 2000) or multiple organ failure, methods for direct visualization and quantitative assessment of the human microcirculation at the bedside are limited. The

interest in microhemodynamic monitoring grows with the understanding of microcirculatory pathology at the molecular level, especially in critically ill patients with sepsis (Esmon *et al.* 1999, Haley *et al.* 2004, Spronk *et al.* 2004). The gold standard for assessment of microcirculation is intravital microscopy (IVM). However, this technique cannot be performed in patients because there is a need for fluorescent dyes and transillumination. The size of instrumentation for IVM can also be a limiting factor for its use in clinical medicine.

For many years, capillary microscopy (capillaroscopy, nailfold videomicroscopy) has been the

only method for assessment of the human microcirculation at the microscopic level *in vivo*. The use of this technique in man is limited to the easy accessible surfaces such as the skin, nailfold, lip or the bulbar conjunctiva (Fagrell 1986, Fagrell and Intaglieta 1997). The nailfold microcirculation is extremely sensitive to external temperature and vasoconstrictive agents (De Baker and Dubois 2001). It has also been reported that nailfold microvascular blood flow was reduced in normotensive febrile patients (Weinberg *et al.* 1991). Thus, the nailfold videomicroscopy may not be a reliable indicator of microcirculation in other parts of the body, particularly in critically ill patients.

Laser Doppler techniques for microvascular imaging are based on frequency shifts in laser light encountering erythrocytes. The role of laser Doppler in microcirculatory imaging is discussed in detail elsewhere (De Baker and Dubois 2001). Laser Doppler has been used to elucidate skin and muscle microcirculation in patients with severe sepsis (Young and Cameron 1995, Neviere *et al.* 1996a,b). Basal blood flow was increased or decreased in these patients compared to that in healthy subjects. The gastric and jejunal mucosal blood flow has also been explored in septic and surgical patients treated with various adrenergic agents (Neviere *et al.* 1996b, Duranteau *et al.* 1999, Thoren *et al.* 2000). The limitation of the laser Doppler technique consists in the measurement of the average of the velocities in all vessels in a defined tissue volume. Thus, this method does not reflect heterogeneity of microvascular blood flow, which is the major characteristic recognized in experimental studies. The scanning laser Doppler technique represents an improvement of the classic laser Doppler method. This technique allows a two dimensional visualization of microcirculation (Essex and Byrne 1991, Nielsen *et al.* 2000).

Orthogonal polarization spectral (OPS) imaging is a relatively new noninvasive method for assessment of human microcirculation. Principles, validation studies, its advantages, limitations and current experience in clinical practice are discussed in this review.

Principles of orthogonal polarization spectral imaging technology

OPS imaging technology was invented by Cytometrics, Inc. (Philadelphia, PA, USA) during the process of developing a videomicroscope able to create high contrast images of blood in the microcirculation

using reflected light (Winkelman 1991). The original purpose was to develop an instrument for analyzing images of the microcirculation using spectrophotometry in order to compute a complete blood count (CBC) without removing blood from the body (Nadeau and Groner 2000).

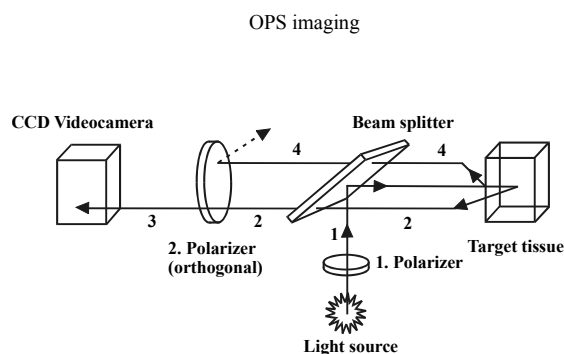


Fig. 1. OPS imaging, optical scheme. (1) Incident polarized light is reflected toward the target tissue by a beam splitter (2). Depolarized scattered light passes through orthogonal polarizer-analyzer and (3) is projected into a CCD videocamera. (4) Reflected polarized light is eliminated by an orthogonal polarizer.

In conventional reflectance imaging (CRI), high-quality image contrast and detail are limited by multiple surface scattering and turbidity of the surrounding tissue (Nadeau and Groner 2000). In OPS imaging, the main difference from CRI consists in the phenomenon of cross-polarization that reduces these effects. As shown in schematically in Fig. 1, incident light is linearly polarized in one plane and projected through a beam splitter onto the subject. Most of the reflected light retain its polarization and cannot pass through the orthogonal polarizer (analyzer) to form the image. The light that penetrates the tissue more deeply and undergoes multiple scattering events becomes depolarized. There is evidence that more than ten scattering events are necessary to depolarize the light effectively (MacKintosh *et al.* 1989, Schmitt *et al.* 1992). Hence, only this depolarized scattered light passing through orthogonal polarizer (analyzer) effectively back-illuminates absorbing material in the foreground. A wavelength of the emitted light (548 nm) was chosen to achieve optimal imaging of the microcirculation because at this wavelength oxy- and deoxy-hemoglobin absorb the light equally. Thus, the blood vessels of the microcirculation can be visualized by OPS imaging. A detailed description of OPS imaging technology and further technical improvements have been published previously (Groner *et al.* 1999, Lindert *et al.*

2002). To resume the principle how the images in OPS are formed there are two main physical effects participating in forming an image in the reflected light: absorption necessary for contrast and scattering for illumination (Groner *et al.* 1999) (Fig. 1). A new device based on OPS technology has been developed – sidestream dark-field (SDF) imaging. In this modality a light guide imaging the microcirculation is surrounded by light-emitting diodes of a wavelength (530 nm) absorbed by the hemoglobin of erythrocytes so that they can be clearly observed as flowing cells. Covered by a disposable cap the probe is placed on tissue surfaces. This method of observing microcirculation provides clear images of the capillaries without blurring (Fig. 2) (Ince 2005).

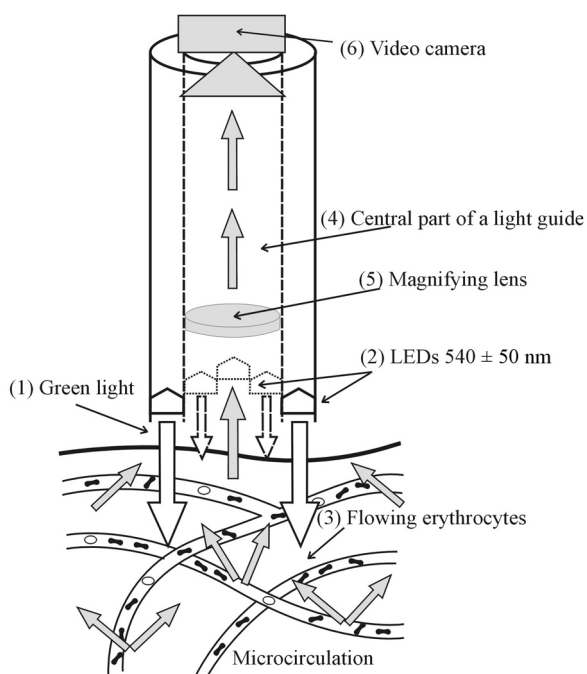


Fig. 2. Sidestream dark-field (SDF) imaging, a scheme. (1) Green light is emitted by (2) peripheral 540±50 nm light-emitting diodes (LEDs) toward tissue arranged in a circle at the end of the light guide. The microcirculation is directly penetrated and illuminated from the side by green light absorbed by hemoglobin of erythrocytes which are observed as a (3) dark moving cells. Imaging central part of light guide (4) is optically isolated from LEDs. A magnifying lens (5) projects the image onto a camera (6).

Validation of OPS imaging

Recent clinical studies of the human microcirculation using OPS imaging in various

pathological states have shown a wide spectrum of different clinical applications with evident impact on the diagnosis, treatment or assessment of prognosis. Thus, considerable effort has been exerted to validate OPS imaging for various clinical purposes. The experimental validation studies are mostly based on comparison of IVM and OPS imaging where IVM is supposed to be a gold standard for main microcirculation parameters assessment (Groner *et al.* 1999, Harris *et al.* 2000a,b, 2002, Laemmel *et al.* 2000, Langer *et al.* 2000, Biberthaler *et al.* 2001, Pahernik *et al.* 2002, von Dobschuetz *et al.* 2003). OPS imaging has been validated especially in animals (Harris *et al.* 2000a,b, 2002, Laemmel *et al.* 2000, Biberthaler *et al.* 2001, Langer *et al.* 2001, von Dobschuetz *et al.* 2003, Pahernik *et al.* 2002, Tugtekin *et al.* 2001) and partly in humans (Mathura *et al.* 2001).

Animal models

Current knowledge on the microcirculation is mainly derived from animal studies. Measurements of the microcirculation in humans were limited to easy accessible surfaces such as skin and nailfold capillaries. The basic validation studies in animals have been performed both on peripheral tissues and solid organs. OPS imaging techniques have been validated using a highly standardized model of the hamster dorsal skinfold chamber (Harris *et al.* 2000a). Four main parameters were measured to validate CYTOSCAN™ A/R against standard fluorescent videomicroscopy under normal conditions and in ischemia/reperfusion injury: functional capillary density (FCD), arteriolar and venular diameter and venular red blood cell (RBC) velocity. There were no significant differences between the two techniques for any of the parameters using Bland-Altman analysis. Similar validation study in ischemia/reperfusion injury realized using the CYTOSCAN E-II has confirmed the comparability of OPS imaging and IVM (Harris *et al.* 2000b). The FCD is defined as the length of RBC-perfused capillaries per unit area and is given in cm/cm². The FCD is a parameter of tissue perfusion and an indirect indicator of the oxygen delivery. It is widely used in clinical studies as a semiquantitative method to determine capillary density and the proportion of perfused capillaries. OPS imaging was also validated against IVM in mouse skin flaps and cremaster muscle preparations. The velocities in straight vessels were comparable in both methods (Laemmel *et al.* 2000). The dorsal skinfold

chamber model in hamsters was also used to validate OPS imaging under conditions of hemodilution with a wide range of hematocrit (Harris *et al.* 2002). Bland-Altman analysis of the vessel diameter and FCD showed good agreement between OPS imaging technique and IVM with a wide range of hematocrit.

OPS imaging has been validated against IVM on solid organs of the rat. The model of ischemia/reperfusion injury of the rat liver has been used for the assessment of hepatic microcirculation applying both techniques (Langer *et al.* 2001). There was significant agreement of data obtained by both methods, correlation parameters for sinusoidal perfusion rate, vessel diameter and venular RBC-velocity were significant. The pancreatic microcirculation has also been under investigation using OPS imaging and IVM (von Dobschuetz *et al.* 2003). Absolute values of the pancreatic functional capillary density did not significantly differ between the two methods. Bland-Altman analyses confirmed good agreement between OPS imaging and IVM. Thus, OPS imaging is a suitable tool for quantitative assessment of pancreatic capillary perfusion during baseline conditions. A murine model of inflammatory bowel disease was applied to validate OPS imaging against IVM for the visualization of colon microcirculation (Biberthaler *et al.* 2001). Postcapillary venular diameter, venular RBC-velocity and FCD were analyzed. All parameters correlated significantly between both methods. The assessment of antivasular tumor treatment using OPS imaging and IVM showed excellent correlation in FCD, diameter of microvessels and RBC-velocity between both techniques (Pahernik *et al.* 2002).

Recently, sepsis-related deterioration in microvascular perfusion has been observed in porcine model of sepsis using OPS imaging. Sublingual microvascular flow and density were assessed by OPS imaging and compared in survivors and non-survivors (Goldfarb *et al.* 2005). OPS imaging reliably assessed alterations of the microvascular circulation during the porcine model of sepsis. The OPS imaging technique has been used for measurement of villus microcirculation during hyperdynamic porcine endotoxemia *via* an ileostomy (Tugtekin *et al.* 2001).

Human studies

Validation studies in man have been limited to easy accessible surfaces, fluorescent intravital microscopy was excluded because of the need to use a

fluorescent dye. Thus, OPS imaging has been validated against conventional capillary microscopy in nailfold skin at rest and after venous occlusion in healthy volunteers (Mathura *et al.* 2001). Results demonstrated that OPS images provided similar values for RBC-velocity and capillary diameter as those measured by conventional capillary microscopy.

Technical limitations

Despite further development and improvement in CYTOSCANTM A/R including a ring illumination and an external more powerful light source compared to CYTOSCAN E-II (Langer *et al.* 2000), several limitations remain. There are two main conditions for successful OPS imaging: 1) to create an image of high quality, and 2) to evaluate the images as quantitatively as possible. Three basic technical limitations have been defined previously (Lindert *et al.* 2002): undesirable pressure of the probe affects blood flow, lateral movement of tissue precludes continuous investigation of selected microvascular region, and blood flow velocities above 1 mm/s are difficult to measure, so that information on arteriolar flow remains unavailable. These limitations have been solved by further technical improvement previously (Lindert *et al.* 2002). A sterilizable device which maintains a fixed distance between probe and tissue has been developed to eliminate movement and pressure artifact as much as possible. Image analysis according to the principle of spatial correlation allows extending the range of detectable blood flow velocities up to 20 mm/s (current technical limit). The methods for image analysis and quantification in clinical practice have been reported previously (De Backer *et al.* 2002), further analysis improvement using flow scoring system has been published recently (Boerma *et al.* 2005). This semi-quantitative analysis of OPS flow imaging has been validated in terms of reproducibility comparing the sublingual microvascular architecture and gut villi in an ileostomy and crypts in a colostomy.

Current clinical use

The technology of OPS-SDF has been incorporated into a small hand-held video-microscope, which can be used in a clinical setting. OPS can assess tissue perfusion using FCD parameter, which is a sensitive parameter for determining the status of

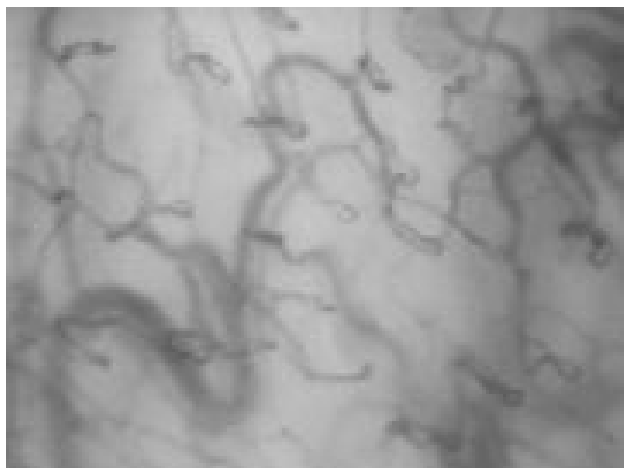

Fig. 3. Sublingual microcirculation by OPS imaging

perfusion in a tissue and also an indirect measure of oxygen delivery. The most easily accessible site in man is the mouth, where OPC produces excellent images of the sublingual microcirculation. There is only weak correlation ($r=0,13$) between the microvascular flow index calculated from paired OPS imaging in the sublingual region and in teeth (Boerma *et al.* 2005). De Backer *et al.* (2002) demonstrated that the sublingual microcirculation in patients with severe sepsis and septic shock was markedly altered and these alterations were more severe in non-survivors. The improvement of microcirculatory alterations in the first 24 h of resuscitation was found to be a better predictor of the outcome than changes in cardiac index, blood pressure or lactate (Sakr *et al.* 2004). OPS imaging was used as an objective bedside method for monitoring effect of the treatment on microcirculatory perfusion, the passive leg

References

- BIBERTHALER P, LANGER S, LUCHTING B, KHANDOGA A, MESSMER K: In vivo assessment of colon microcirculation: comparison of the new OPS imaging technique with intravital microscopy. *Eur J Med Res* **6**: 525-34, 2001.
- BOERMA C, MATHURA KR, VAN DER VOORT P, SPRONK PE, INCE C: Quantifying bedside-derived imaging of microcirculatory abnormalities in septic patients: a prospective validation study. *Crit Care* **9**: R601-R606, 2005.
- BOLLINGER A, FAGRELL B (Ed): *Clinical Capillaroscopy: A Guide to Its Use in Clinical Research and Practice*. Hogrefe & Huber Publishers, Toronto, 1990.
- DE BACKER D, DUBOIS MJ: Assessment of the microcirculatory flow in patients in the intensive care unit. *Curr Opin Crit Care* **7**: 200-203, 2001.
- DE BACKER D, CRETEUR J, PREISER JC, DUBOIS MJ, VINCENT JL: Microvascular blood flow is altered in patients with sepsis. *Am J Respir Crit Care Med* **166**: 98-104, 2002.

elevation resulted in a rise of sublingual capillary perfusion in hypovolemic patients (Spronk and Ziekenhuizen 2005).

However, several limitations of the OPS technique in clinical use have to be pointed out. Current OPS technology can investigate only tissues covered by a thin epithelial layer and therefore internal organs are not accessible, except for perioperative use. Movement artifacts, a semiquantitative measure of perfusion, observer-related bias and also inadequate sedation may limit the quality of obtained data and its correct interpretation.

Conclusions

Despite limitations of OPS, this technology represents a promising noninvasive tool for evaluating microcirculation in both experimental and, maybe even more importantly, in a clinical setting, especially in critically ill patients. Further improvements in the technology are pending, they will probably bring rapid online analysis of obtained data. Microcirculation plays a key role in tissue oxygenation and there are many physiological and pathological conditions affecting microcirculation differently in various organs and tissues. The availability of monitoring microcirculation by using OPS or SDF imaging technology is not only of great potential for obtaining new informations about human physiology, but also to change our treatment strategies we have been used to.

Acknowledgements

Research project MZO 00179906.

- DURANTEAU J, SITBON P, TEBOUL JL, VICAUT E, ANGUEL N, RICHARD CH, SAMII K: Effects of epinephrine, norepinephrine, or the combination of norepinephrine and dobutamine on gastric mucosa in septic shock. *Crit Care Med* **27**: 893-900, 1999.
- ESMON CT, FUKUDOME K, MATHER T, BODE W, REGAN LM, STEARNS-KUROSAWA DJ, KUROSAWA S: Inflammation, sepsis and coagulation. *Hematologica* **84**: 254-259, 1999.
- ESSEX TJ, BYRNE PO: Doppler scanner for imaging blood flow in skin. *J Biomed Eng* **13**: 189-194, 1991.
- FAGRELL B: Microcirculatory methods for the clinical assessment of hypertension, hypotension, and ischemia. *Ann Biomed Eng* **14**: 163-173, 1986.
- FAGRELL B, INTAGLIETA M: Microcirculation: its significance in clinical and molecular medicine. *J Intern Med* **241**: 349-362, 1997.
- GOLDFARB RD, GUGLIELMI M, ROSS F, PURNACHANDRA J, CARCASSES AA, TRZECIAK S, ZANOTTI S, DELLINGER R, PARRILLO JE, HOLLENBERG SM: Orthogonal polarization spectral imaging demonstrates sepsis-related deterioration in microvascular perfusion. *FASEB J* **19**: Abstract #691.14, 2005.
- GRONER W, WINKELMAN JW, HARRIS AG, INCE C, BOUMA GJ, MESSMER K, NADEAU RG: Orthogonal polarization spectral imaging: a new method for study of the microcirculation. *Nat Med* **5**: 1209-1212, 1999.
- HALEY M, CUI X, MINNECI PC, DEANS KJ, NATANSON C, EICHACKER PQ: Activated protein C in sepsis: emerging insights regarding its mechanism of action and clinical effectiveness. *Curr Opin Infect Dis* **17**: 205-211, 2004.
- HARRIS AG, SINITSINA I, MESSMER K: Quantitative analysis of orthogonal polarization spectral images: validation in the hamster dorsal skinfold chamber In: *Orthogonal Polarization Spectral Imaging*. MESSMER K (ed). Karger, Basel, Vol 24, 2000a, pp 21-31.
- HARRIS AG, SINITSINA I, MESSMER K: The Cytoscan Model E-II, a new reflectance microscope for intravital microscopy: comparison with the standard fluorescence method. *J Vasc Res* **37**: 469-476, 2000b.
- HARRIS AG, SINITSINA I, MESSMER K: Validation of OPS imaging for microvascular measurements during isovolumic hemodilution and low hematocrits. *Am J Physiol* **282**: H1502-H509, 2002.
- INCE C: Sidestream dark field imaging: an improved technique to observe sublingual microcirculation. *Critical Care* **9** (Suppl 1): P72, 2005.
- LAEMMEL E, TADAYONI R, SINITSINA I, BOCZKOWSKI J, VICAUT E: Using Orthogonal polarization spectral imaging for the experimental study of microcirculation: comparisons with intravital microscopy. In: *Orthogonal Polarization Spectral Imaging*. MESSMER K (ed). Karger, Basel, Vol 24, 2000, pp 50-60.
- LANGER S, VON DOBSCHUETZ E, HARRIS AG, KROMBACH F, MESSMER K: Validation of the orthogonal polarization spectral imaging technique on solid organs. In: *Orthogonal Polarization Spectral Imaging*. MESSMER K (ed). Karger, Basel, Vol 24, 2000, pp 32-46.
- LANGER S, HARRIS AG, BIBERTHALER P, VON DOBSCHUETZ E, MESSMER K: Orthogonal polarization spectral imaging as a tool for the assessment of hepatic microcirculation: a validation study. *Transplantation* **71**: 1249-1256, 2001.
- LEHR HA, BITTINGER F, KIRKPATRICK CJ: Microcirculatory dysfunction in sepsis: a pathogenetic basis for therapy? *J Pathol* **190**: 373-386, 2000.
- LINDERT J, WERNER J, REDLIN M, KUPPE H, HABAZETTL H, PRIES AR: OPS imaging of human circulation: a short technical report. *J Vasc Res* **39**: 368-372, 2002.
- MACKINTOSH FC, ZHU JX, PINE DJ, WEITZ DA: Polarization memory of multiply scattered light. *Phys Rev B* **40**: 93-42, 1989.
- MATHURA KR, VOLLEBREGT KC, BOER K, DE GRAAFF JC, UBBINK DT, INCE C: Comparison of OPS imaging and conventional capillary microscopy to study the human microcirculation. *J Appl Physiol* **91**: 74-8, 2001.
- NADEAU RG, GRONER W: Orthogonal polarization spectral imaging: State of the Art. In: *Orthogonal Polarization Spectral Imaging*. MESSMER K (ed). Karger, Basel, Vol 24, 2000, pp 9-20.
- NEVIERE R, MATHIEU D, CHAGNON JL, LEBLEU N, MILLIEN JP, WATTEL F: Skeletal muscle microvascular blood flow and oxygen transport in patients with severe sepsis. *Am J Respir Crit Care Med* **153**: 191-195, 1996a.

- NEVIERE R, MATHIEU D, CHAGNON JL, LEBLEU N, WATTEL F: The contrasting effects of dobutamine and dopamine on gastric mucosal perfusion in septic patients. *Am J Respir Crit Care Med* **154**: 1684-1688, 1996b.
- NIELSEN AN, FABRICIUS M, LAURITZEN M: Scanning laser-Doppler flowmetry of rat cerebral circulation during cortical spreading depression. *J Vasc Res* **37**: 513-522, 2000.
- PAHERNIK S, HARRIS AG, SCHMITT-SODY M, KRASNICI S, GOETZ AE, DELLIAN M, MESSMER K: Orthogonal polarisation spectral imaging as a new tool for the assessment of antivascular tumour treatment in vivo: a validation study. *Br J Cancer* **86**: 788-95, 2002.
- SAKR Y, DUBOIS MJ, DE BACKER D, CRETEUR J, VINCENT JL: Persistent microvasculatory alterations are associated with organ failure and death in patients with septic shock. *Crit Care Med* **32**: 1825-1831, 2004.
- SCHMITT JM, GANDJBAKHCHAH AH, BONNER RF: Use of polarized light to discriminate short-pass photons in a multiply scattering medium. *Appl Opt* **31**: 6535, 1992.
- SPRONK PE, ZANDSTRA DF, INCE C: Bench-to-bedside review: sepsis is a disease of microcirculation. *Crit Care* **8**: 462-468, 2004.
- SPRONK P, ZIEKENHUIZEN G: The response of the microcirculation to volume. In: *Abstracts of the 2nd International Symposium on Microcirculation and Mitochondrial Dysfunction in Intensive Care Medicine*, Amsterdam, 2005, p. 29.
- THOREN A, ELAM M, RICKSTEN SE: Differential effects of dopamine, dopexamine, and dobutamine on jejunal mucosal perfusion early after cardiac surgery. *Crit Care Med* **28**: 2338-2343, 2000.
- TOOKE JE: Microvasculature in diabetes. *Cardiovasc Res* **32**: 764-771, 1996.
- TUGTEKIN IF, RADERMACHER P, THEISEN M, MATEJOVIC M, STEHR A, PLONER F, MATURA K, INCE C, GEORGIEFF M, TRAGER K: Increased ileal-mucosal-arterial PCO₂ gap is associated with impaired villus microcirculation in endotoxic pigs. *Intensive Care Med* **27**: 757-766, 2001.
- VON DOBSCHUETZ E, BIBERTHALER P, MUSSACK T, LANGER S, MESSMER K, HOFFMANN T: Noninvasive in vivo assessment of the pancreatic microcirculation: orthogonal polarization spectral imaging. *Pancreas* **26**: 139-143, 2003.
- WEINBERG JR, BOYLE P, THOMAS K, MURPHY K, TOOKE JE, GUZ A: Capillary blood cell velocity is reduced in fever without hypotension. *Int J Microcirc Clin Exp* **10**: 13-19, 1991.
- WINKELMAN JW: Apparatus and method for in vivo analysis of red and white blood cell indices (4998553). USA, patent. 3-12-1991.
- YOUNG JD, CAMERON EM: Dynamics of skin blood flow in human sepsis. *Intensive Care Med* **21**: 668-674, 1995.

Corresponding author

V. Černý, Faculty of Medicine, Department of Anesthesiology and Intensive Care Medicine, University Hospital, 500 05 Hradec Kralove, Czech Republic. E-mail: cernyvla@fnhk.cz